

Robotic-Assisted Major Pancreatic Resection

H.J. Zeh III, MD*, David L. Bartlett, MD, A. James Moser, MD*

Division of Surgical Oncology, Department of Surgery, University of Pittsburgh School of Medicine, Suite 417, UPMC Cancer Pavilion, 5150 Center Avenue, Pittsburgh, PA 15232, USA

HISTORICAL LANDMARKS IN DEVELOPMENT OF THE PANCREATICODUODENECTOMY

The first published report of a successful pancreaticoduodenectomy was published by Allen O. Whipple in 1935 [1]. Whipple reported 3 patients who underwent a 2-stage procedure with pancreatic duct ligation: one patient died in the perioperative period; another died 8 months later from cholangitis, and the last from metastases after 28 months. This initial report was followed by a series describing a single-stage procedure [2], the fundamentals of which we recognize today as the Whipple procedure. These fundamentals included (1) resection and reconstruction in one stage; (2) avoidance of cholecystoenterostomy by implantation of the bile duct into the jejunum, and (3) implantation of the pancreatic duct into the jejunum. Following the modification of pylorus preservation by Traverso and Longmire [3], the technical aspects of pancreaticoduodenectomy have remained essentially unchanged since Whipple described the procedure in 1935.

Postoperative mortality and morbidity remained significant hurdles to the widespread implementation of pancreaticoduodenectomy for many years after the initial description. Mortality rates approaching 30% were common for the next several decades. In 1968 John Howard reported a series of 41 consecutive pancreaticoduodenectomies without a mortality [4]. This series was followed by improvements by John Cameron and colleagues [5] at Johns Hopkins, who standardized the technical aspects of this procedure and set the modern-day gold standard for outcomes. Attention to surgical detail combined with advances in critical care and anesthesia led to steady and dramatic improvements in postoperative outcomes following pancreaticoduodenectomy. Recent reports reproducibly demonstrate a morbidity rate of 30% to 40% with 1% to 3% mortality [6].

Recent refinements of the pancreaticoduodenectomy have focused on the implementation of minimally invasive approaches. Gagner and Pomp [7] described the first laparoscopic pancreaticoduodenectomy in 1994, a procedure that lasted nearly 24 hours. Since then, Kendrick and Cusati [8] and Palenivelu and colleagues [9] have reported large series of minimally invasive

*Corresponding authors. *E-mail addresses:* zehh@upmc.edu; moseraj@upmc.edu

pancreaticoduodenectomies with outcomes comparable with those of large open series. Most recently, robotic-assisted minimally invasive approaches have been described by the groups led by Gulianotti, Melvin, Zeh, and Moser [10–12].

POTENTIAL ADVANTAGES OF MINIMALLY INVASIVE MAJOR PANCREATIC RESECTION

Major pancreatic resection remains the final frontier of minimally invasive surgery, because of the twin technical challenges of controlling hemorrhage from major vessels and reconstructing the biliary and pancreatic ducts with acceptable morbidity (Box 1). The minimally invasive approach offers potential advantages compared with open surgery: (1) decreased incisional pain may lead to improved recovery time and decreased hospital stay; (2) improved post-operative recuperation and performance status may permit earlier initiation of adjuvant therapy in a higher percentage of patients with pancreatic cancer [13]. It is important that initial concerns regarding the oncologic equivalency of minimally invasive resection for cancer have proved to be unfounded in other malignancies such as colon and gastric cancer [12,14–16]. The third potential advantage of minimally invasive pancreatic resection applies to the group of patients with radiographically identifiable precursor lesions such as mucinous cystic neoplasms who may require prophylactic pancreatectomies to prevent the progression to pancreatic cancer. The availability of a minimally invasive approach with equivalent or superior recovery times might alter the risk/benefit ratio of pancreatectomy in favor of earlier intervention and improve patient acceptance of prophylactic surgery. Lastly, the technological progression in all of surgery is toward smaller more minimally invasive procedures. Reluctance or refusal on the part of hepatic/pancreatic/biliary tract (HPB) surgeons to explore innovations risks obsolescence.

LIMITATIONS OF LAPAROSCOPIC TECHNIQUES FOR PANCREATICODUODENECTOMY

Laparoscopic surgery has evolved significantly since its introduction in the early 1970s. Although advanced laparoscopic procedures are being performed at many centers, advanced procedures that require complicated resection and

Box 1: Potential advantages of minimally invasive pancreaticoduodenectomy

1. Reduced perioperative morbidity
2. Better LOS and return to function
3. Higher rate of discharge to home
4. Decreased blood loss and need for transfusion
5. Increased rate and higher use of postoperative adjuvant therapy
6. Better acceptance of prophylactic pancreatectomy

reconstruction such as pancreaticoduodenectomy (PD) remain limited to a few specialized centers. A total of only 146 laparoscopic PDs were reported in the world's literature in the first 14 years following Gagner's description in 1994 [17]. Palanivelu and colleagues [9] presented 75 cases, and Kendrick and Cusati [8] reported 62 cases of totally laparoscopic PDs. These two series demonstrate that laparoscopic pancreaticoduodenectomy can be performed safely with acceptable morbidity, although their results may be difficult to generalize to other centers [18]. The slow implementation of laparoscopic techniques for pancreaticoduodenectomy is likely the result of the limitations inherent to current technology, namely, 2-dimensional imaging, limited range of instrument motion, and poor surgeon ergonomics [17]. In this situation the surgical principles are altered to meet the limitations of the technology, leading to reluctance on the part of many HPB surgeons. A minimally invasive approach to pancreaticoduodenectomy that recreates well-established surgical principles would be a significant advance.

ROBOTIC-ASSISTED MINIMALLY INVASIVE PANCREATICODUODENECTOMY

Robotic-assisted minimally invasive surgery overcomes many of the shortcomings of laparoscopy, with improved 3-dimensional imaging, 540° movement of surgical instruments, and improved surgeon comfort and precision [19] (Box 2). These technological innovations allow complex resections and anastomotic reconstructions to be performed with techniques identical to open surgery. The authors present here their technical description and outcomes with robotic-assisted major pancreatic resections. This approach maintains maximal adherence to the traditional open surgical techniques with a minimally invasive approach.

SELECTION CRITERIA FOR ROBOTIC-ASSISTED PANCREATICODUODENECTOMY

To maintain safety and transparency of surgical outcomes, all potential candidates for robotic pancreatic resection are reviewed by the Surgical Oncology Robotic Selection Committee. All robotic procedures are performed by two expert pancreatic surgeons familiar with open pancreaticoduodenectomy and capable of carrying out venous resection and reconstruction whenever indicated. Patients with periampullary malignancies who are candidates for robotic

Box 2: Potential advantages of robotic-assisted minimally invasive pancreatic resection

1. Magnification 20×–30×
2. Near 540° range of motion in instruments
3. Elimination of tremor/improved dexterity
4. Improved surgeon comfort
5. Stereotactic binocular visualization

pancreaticoduodenectomy undergo individualized treatment planning based on a validated predictive model to select candidates with the highest likelihood of achieving an R0 surgical resection. The prediction rule was developed and validated in independent cohorts of patients with potentially resectable pancreatic cancer [20]. The model stratifies patients into low risk and high risk for non-R0 surgical outcomes based on findings during preoperative computed tomography (CT) and endoscopic ultrasonography (EUS). High-risk patients are not offered the robotic approach and instead undergo traditional open pancreaticoduodenectomy, given the potential for robotic surgery to compromise oncologic principles in these high-risk patients. Low-risk patients are offered robotic surgery after a detailed consent process and enrollment in a prospective registry of robotic pancreatic surgery.

The predictive factors are: (1) any evidence of arterial or venous vascular involvement on CT; (2) the combination of EUS T-stage and N-stage data to assign a preoperative stage according to the criteria of the American Joint Committee on Cancer (sixth edition), and largest EUS tumor dimension greater than 2.6 cm. Evidence for vascular involvement by CT scan includes minimal abutment of the superior mesenteric or hepatic arteries without extension to the celiac axis, as well as any preoperative suspicion that tumor involves the superior mesenteric vein (SMV)-portal vein (PV) confluence despite the possibility of venous resection and reconstruction. The prediction rule classifies operative findings of metastatic or locally advanced disease as well as positive resection margins as treatment failures. A patient is considered a good candidate for R0 resection (low risk) and should undergo surgery as primary therapy if: (a) the EUS stage is 1A; (b) if there is no vascular involvement, and the EUS stage is greater than 1A and less than 3; or (c) if there is no vascular involvement and EUS stage 2B but the largest tumor dimension is less than 2.6 cm. Otherwise, a patient is a poor candidate for R0 resection (high risk).

In the authors' published report, the overall resection rate (R0 + R1) among low-risk patients was significantly greater (92%) than that of the high-risk group (53%; $P < .0002$). Low-risk patients achieved R0 status more frequently than high-risk patients (73% vs 33% R0, $P = .0009$), despite resection and reconstruction of the PV whenever indicated in both groups. Additional operative findings distinguishing the two risk groups included a greater proportion of unresectable, locally advanced tumors (17% vs 0%, $P = .007$) as well as unexpected metastatic disease (30% vs 8%, $P = .026$) in the high-risk group. High predicted risk of surgical failure corresponded to more advanced stages of disease on final surgical pathology, and also correlated with shorter postoperative overall survival. Median survival of low-risk patients was 20.3 months, compared with 12.1 months in those considered at high risk ($P = .02$).

TECHNIQUE OF ROBOTIC-ASSISTED PANCREATICODUODENECTOMY

Robotic-assisted minimally invasive resection of the pancreatic head recreates published methods for open pancreaticoduodenectomy. The technique emphasizes

teamwork between two experienced pancreatic surgeons and requires 4-handed cooperation to retract and expose critical structures, the anatomy of which may be distorted by tumor, body habitus, and pancreatitis. The importance of teamwork cannot be overemphasized. Exposure and safe control of bleeding from major vascular structures requires two surgeons familiar with the anatomy to develop a skilled collaboration and the mutual ability to anticipate each other's movements.

Instruments

Standard laparoscopic instruments are used to explore the abdomen, mobilize the right colon, elevate the pancreatic head from the retroperitoneum (Kocher maneuver), and divide the proximal duodenum and jejunum. Free mobility of the table is possible during laparoscopy, allowing gravity to act as a retractor. The dissection begins with a 45° angled laparoscope, atraumatic graspers, suction, and the LigaSure (Covidien, Boulder, CO, USA). After mobilization of the pancreatic head and division of the duodenum, the da Vinci Si robotic platform (Intuitive Surgical, Sunnyvale, CA, USA), is used for the portal dissection and subsequent reconstruction, assisted by the laparoscopic cosurgeon seated between the patient's legs.

Patient position

The patient is positioned supine on a split-leg table with the arms tucked. Invasive central and arterial lines are inserted in addition to a nasogastric tube and Foley catheter. The distance between the umbilicus and the head of the table is measured to keep the robotic camera arm within design parameters (the "sweet spot"). An upper body convective warming blanket is used to maintain normothermia.

Port position

Seven laparoscopic ports are typically required. The 5-mm optical separator is used to access the peritoneal cavity in the left subcostal region and is later converted to a robot port. The camera port is placed 2 to 3 cm to the right of the midline at the level of the umbilicus to improve exposure of the PV. Two 8-mm robotic ports (R1 and R3) are placed approximately in the right upper quadrant. A 5-mm port for the laparoscopic liver retractor is inserted in the anterior axillary line. Two assistant ports (A1 and A2) are placed in the lower quadrants.

Step 1

The first step involves mobilization of the right colon and exposure of the pancreatic head (Kocher maneuver). Following insufflation and laparoscopic staging to exclude unrecognized metastases (Fig. 1), the falciform ligament is sewn to the anterior abdominal wall to elevate the liver and prevent smearing of the camera. The retroperitoneal attachments of the hepatic flexure are divided, and the right colon is rotated medially down to the terminal ileum to expose the SMV at the root of the small bowel mesentery. This action is performed from the left side of the table with the LigaSure device and an atraumatic grasper (ports R1 and A2). An automated liver retractor is inserted through a 5-mm port in the far lateral right upper quadrant to expose the porta

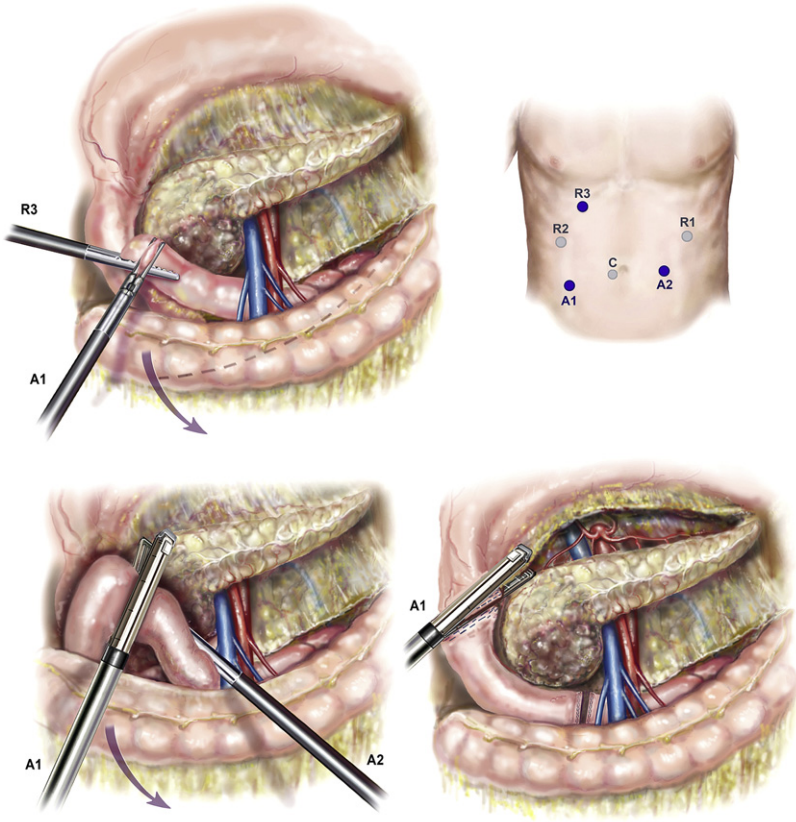


Fig. 1. Mobilization of the right colon, Kocher maneuver, and division of duodenum. (Courtesy of Randal S. McKenzie, McKenzie Illustrations.)

hepatis. The retroperitoneal investment of the third portion of the duodenum is divided and the pancreatic head elevated from the retroperitoneum up to the origin of the superior mesenteric artery (SMA). Next, an extended Kocher maneuver is performed from the right side of the table to release the proximal jejunum from the mesenteric vessels. The jejunum is pulled into the right upper quadrant and is transected with a 3.5-mm linear cutting stapler approximately 10 cm distal to the former ligament of Treitz. The jejunum is marked with an Endostitch 50 to 60 cm distally to mark the duodenojejunostomy, and the jejunum is passed beneath the mesenteric vessels and the stitch located. The jejunum is then tacked to the greater curvature of the stomach to allow for easy identification during reconstruction after the Robot is docked.

Step 2: Division of the gastrocolic omentum and proximal duodenum

The gastrocolic omentum is divided in the avascular plane between the ventral and dorsal mesogastrium (see Fig. 1). The posterior stomach is mobilized from

the anterior surface of the pancreas, and the left gastric vessels are identified. The groove between the gastroepiploic vascular pedicle and duodenum is opened with the LigaSure, elevating the first portion of the duodenum from the pancreatic head. The right gastric artery is clipped and divided with the LigaSure, completing the mobilization of the duodenum, which is then divided with a linear cutting stapler (port A1). The gastroepiploic pedicle is divided with a vascular stapler, preserving the vessels along the greater curve but leaving the prepyloric lymph nodes in continuity with the specimen.

Step 3: Docking the robot

The table is positioned right-side up in steep reverse Trendelenburg position. The robot is docked directly over the head of the table with 2 arms on the patient's right, insuring that the liver retractor does not conflict with inferior robotic arm. The robotic surgeon operates the da Vinci console while the laparoscopic surgeon stands or sits between the patient's legs to manage the suction irrigator, exchange instruments, pass needles, and operate the LigaSure as needed. Following docking of the robot, the remainder of the procedure is a 5-handed procedure with the robotic surgeon using ports R1 to R3 and the assistant operating through A1 and A2.

Step 4: Dissection of the porta hepatis and division of the bile duct

The common hepatic artery lymph node (station 8a) is mobilized with robotic cautery and transected with the LigaSure device to expose the superior border of the pancreas and the common hepatic artery (CHA) (Fig. 2). The CHA is followed distally into the porta hepatis to demonstrate the origin of the divided

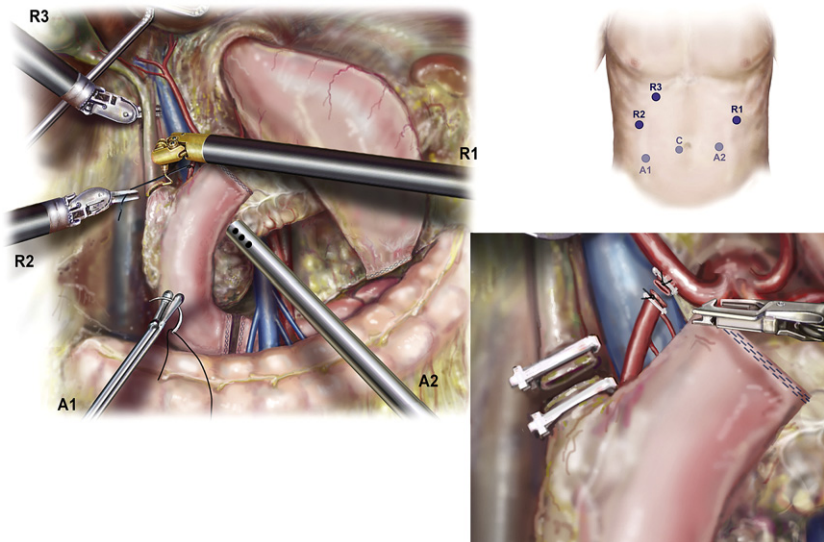


Fig. 2. Portal dissection. (Courtesy of Randal S. McKenzie, McKenzie Illustrations.)

right gastric artery and trunk of the gastroduodenal artery (GDA), which is cleared of sufficient surrounding tissue to be divided safely. The PV is exposed posteriorly. A test occlusion of the GDA is performed, and flow in the CHA is verified by maintenance of visible pulsatile flow or laparoscopic B-D mode ultrasound captured in the patient console. The GDA is tied with 2-0 silk proximally and divided with a vascular stapler, ties, or 4-0 Prolene suture ligature depending on access to the porta hepatis from the assistant port. The PV is dissected into the hepatic hilum to demonstrate the medial edge of the common hepatic duct, and nodal tissue to be swept into the specimen in the process with the vessels in view. Lymph nodes along the lateral margin of the bile duct are cleared, taking care to identify aberrant right hepatic arterial anatomy. The bile duct is divided with robotic cautery scissors after a proximal Hem-o-lock clip (Teleflex, Research Triangle Park, NC, USA) is applied to prevent contamination of the peritoneum with bile. The distal margin is resected and sent for pathologic examination.

Step 5: Dissection of the pancreatic neck and mobilization of the portal vein

The origin of the right gastroepiploic vein is identified in addition to the SMV and middle colic vein (Fig. 3). These large tributary veins are either ligated or divided between 2-0 silk ties or a vascular stapler. The SMV is dissected free of

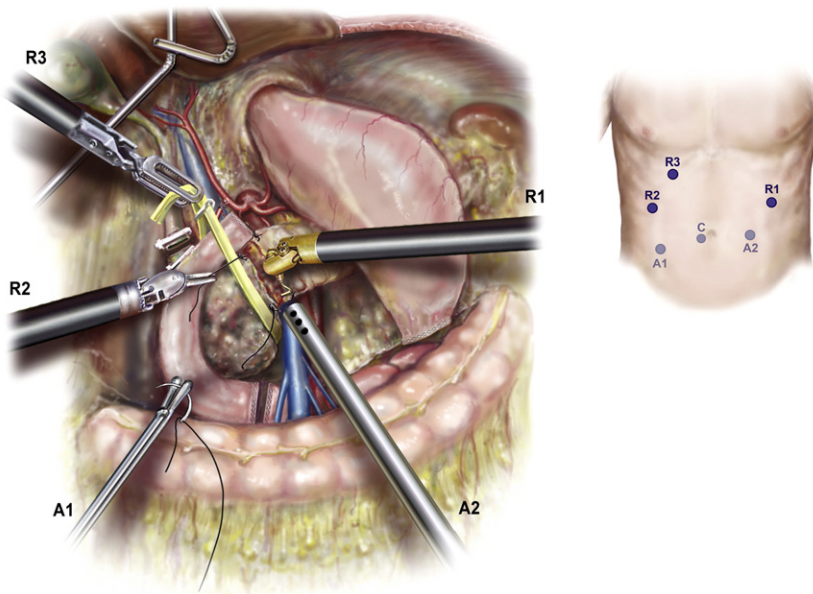


Fig. 3. Dissection of the pancreatic neck. (Courtesy of Randal S. McKenzie, McKenzie Illustrations.)

the posterior surface of the pancreatic neck, and an articulated laparoscopic grasper is used to pass an umbilical tape around the pancreas. Identical to the open technique, 2-0 silk sutures are used to occlude the transverse pancreatic arteries at the inferior and superior borders of the pancreas, and the pancreas is divided with the cautery hook. The pancreatic margin is resected from the head, inked, and sent to pathology for frozen section.

Step 6: Dissection of the retroperitoneal margin

The pancreas is elevated from the retroperitoneum with a “hanging maneuver” using the third robotic arm (R3) (Fig. 4). The lateral margin of the SMV-PV is exposed and mobilized using robotic scissors in a caudad to cephalad direction, and venous tributaries are individually ligated with 3-0 silk suture. Very small side branches may be addressed using a 5-mm clip applicator, but caution should be used when applying these as they may become dislodged during later manipulation. The superior pancreaticoduodenal vein (vein of Belcher) is divided between silk ties or with a vascular stapler depending on its caliber. Next (Fig. 5), using the robotic Maryland dissector, the adventitia of the SMA is identified just above where the first jejunal branch crosses. Several small but sensitive branches from the genu of the first jejuna branch of the SMV often need to be ligated to expose the SMA. The authors have found 4-0 Prolene suture ligation with ports R2 and R1 to be the safest and most efficient method to address these branches. The SMA lymph nodes usually found posterior but now retracted lateral to the SMA are divided using LigaSure with the SMA in view. Tiny arterial branches are divided with the LigaSure device, whereas clips and LigaSure and 4-0 Prolene suture ligatures are used together

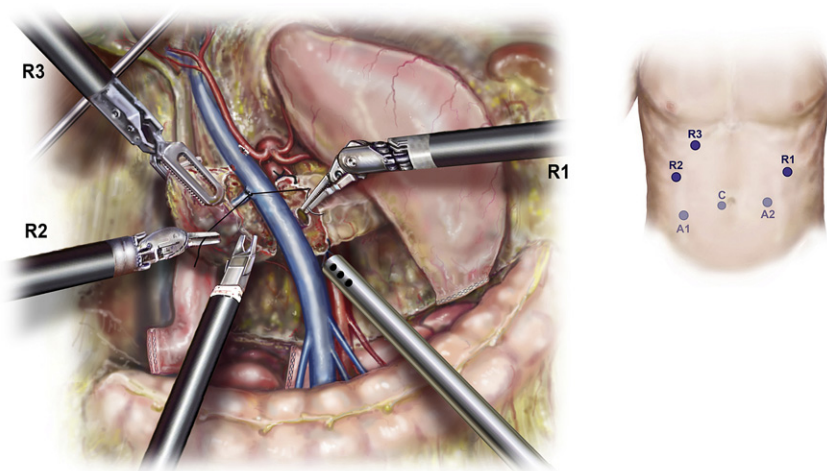


Fig. 4. Mobilization of the portal vein. (Courtesy of Randal S. McKenzie, McKenzie Illustrations.)

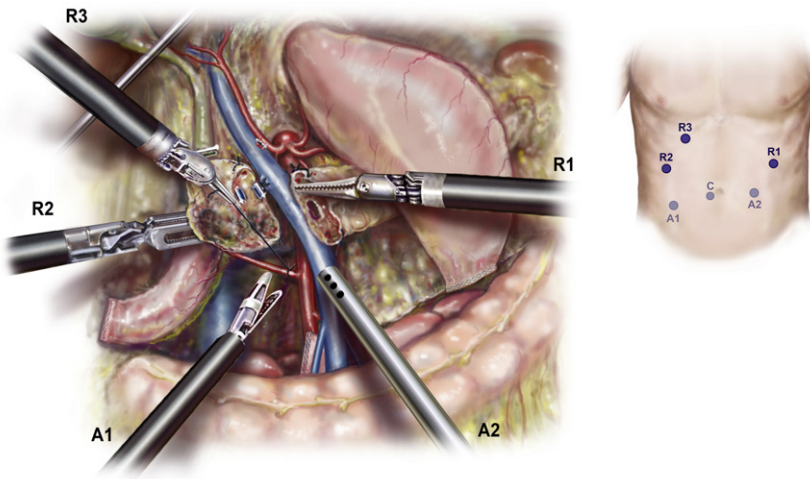


Fig. 5. Dissection of the retroperitoneal margin. (Courtesy of Randal S. McKenzie, McKenzie Illustrations.)

on larger vessels, keeping the plane of Leriche in view. The inferior and superior pancreaticoduodenal vessels are divided between 2-0 silk ligatures, with 5-mm clips and LigaSure being used for smaller perforators and the duodenal mesentery. The exposure allows 4-0 or 5-0 Prolene to be used to control bleeding or suture ligation of larger tributaries through ports R2 and R3. The assistant is able to retract and maintain suction in the surgical field through A1 and A2.

Once the specimen is freed, it is placed within a large specimen bag that is sealed and left in the abdomen for extraction at the end of the procedure. The retroperitoneal margin is irrigated and inspected for bleeding, and gold fiducials are placed in cases of suspected malignancy. The gallbladder is mobilized in an antegrade fashion, dividing the cystic artery and duct between clips.

Step 7

Robotic gastrointestinal reconstruction is performed in a fashion identical to the open technique, with the sole exception being the substitution of multifilament absorbable 5-0 suture for monofilament. A 2-layer, end-to-side, duct-to-mucosa pancreaticojejunostomy is performed using the modified Blumgart technique. Interrupted pancreatic duct sutures are placed first to facilitate visualization of the ductal mucosa (5-0 Vicryl) using alternating dyed and undyed sutures, which are clipped and reflected out of the way (Fig. 6). Next, transpancreatic, 2-0 silk horizontal mattress sutures are passed to anchor the seromuscular layer of the jejunum to the pancreatic parenchyma. A small enterotomy is made using robotic cautery shears, and an interrupted duct-to-mucosa anastomosis is completed. When necessary, a pancreatic duct stent (5-7F, 7-cm Zimmon

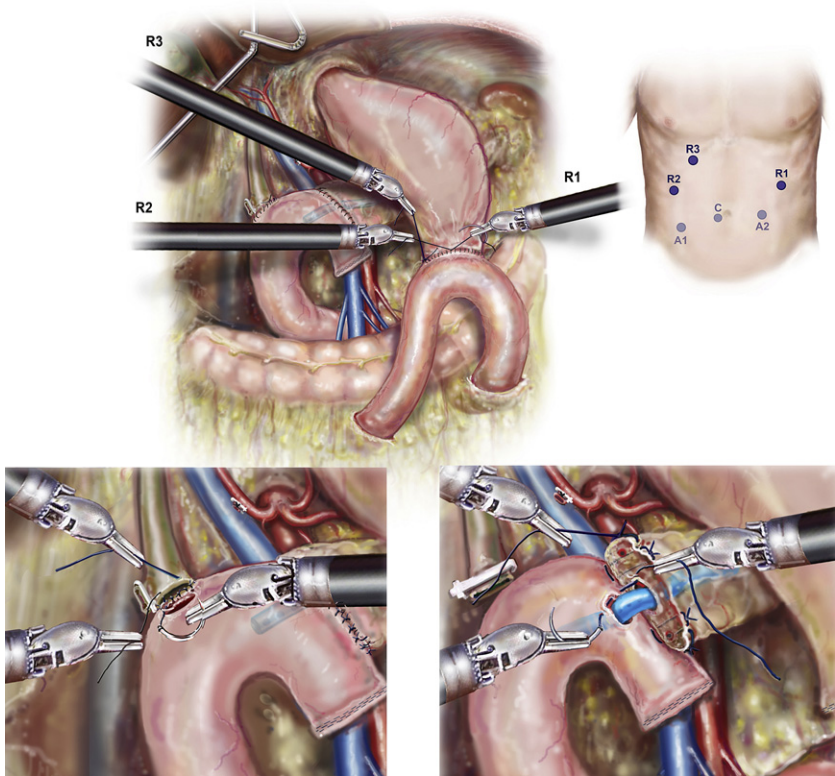


Fig. 6. Reconstruction. (Courtesy of Randal S. McKenzie, McKenzie Illustrations.)

pancreatic stent; Cook Medical, Bloomington, IN, USA) is placed to assure duct patency. Secretin (intravenously) is administered to stimulate pancreatic secretion in cases of tiny ducts not being visible despite repeated inspection. The anastomosis is completed with an anterior layer of 2-0 silk sutures. Approximately 10 cm downstream from the pancreaticojejunostomy, a single-layer end-to-side hepaticojejunostomy is created with 5-0 Vicryl. The suture is placed in a running fashion for duct diameters greater than 5 mm in diameter when visualization is optimal, or in interrupted fashion otherwise. Finally, an antecolic hand-sewn duodenojejunosomy is performed with a posterior layer of interrupted 2-0 silk followed by running 3-0 Vicryl after the duodenum and jejunum are opened. A Connell technique is used anteriorly. An anterior layer of seromuscular sutures is placed.

After assuring hemostasis and a correct needle count, two round 19F surgical drains are placed, one anterior and one posterior to the biliary and pancreatic anastomoses. The specimen bag is grasped through the right lower quadrant port site. The robot is undocked, and the right lower quadrant incision is enlarged as necessary to extract the specimens. All ports over 8 mm are closed

with the carter thompson device and 0-vicryl suture. All skin incisions are closed with 3-0 Vicryl and Inderamil Glue™. Patients are awakened, extubated, and transferred to the surgical intensive care unit for overnight observation.

PITTSBURGH EXPERIENCE WITH ROBOTIC-ASSISTED MAJOR PANCREATIC RESECTION

In addition to 40 distal pancreatectomies, 51 patients have undergone robotic-assisted major pancreatectomy at the University of Pittsburgh Medical Center since October 2008. Procedures included 42 robotic-assisted pancreaticoduodenectomies (RAPD), 5 central pancreatectomies (RACP), 2 total pancreatectomies (RATP), and 2 duodenum-preserving pancreatic head resections (Frey procedure) with lateral pancreaticojejunostomy (RAFP). The leading indication for surgery was suspected malignancy in 35 patients (66%), premalignant lesions in 9 (17%), and 6 (11%) with benign cysts or calcific chronic pancreatitis. Final pathologic diagnoses are shown in Table 1. Median age of the patients was 70 (range 27–85) years, and 62% (30) were female. Median operative time for the completed procedures was 560 minutes (range 327–848 minutes), including the time to drape and dock the robot (approximated to be 30–45 minutes per case) but excluding general room setup time. Median blood loss was 300 mL (range 50–2000 mL). Twelve patients (20%) required perioperative blood transfusion within 72 hours of surgery. Median hospital length of stay was 10 days (range 4–87 days), with one postoperative death on day 87 (Table 2).

To stratify anastomotic risk, pancreatic remnants were classified by International Study Group of Pancreatic Surgery (ISGPS) criteria [16] including: duct diameter (Types I–III), consistency of the gland (A = soft/normal, B = firm/hard/fibrotic), and length of pancreatic remnant mobilized (pancreatic mobilization 1–3 cm) prior to anastomosis (Table 3). The higher than expected ratio of

Table 1
Final histologic diagnosis (N = 51)

Diagnosis	n (%)
Ampullary adenocarcinoma	9 (18)
Pancreatic ductal adenocarcinoma	14 (26)
Neuroendocrine tumor	9 (18)
Intraductal papillary mucinous neoplasm	6 (12)
Mucinous cystic neoplasm	2 (4)
Serous cystic adenoma	3 (6)
Chronic pancreatitis	3 (4)
Solid pseudopapillary neoplasm	2 (4)
Adenoma	1 (2)
GIST	1 (2)
CCA	2 (4)

One patient had GIST and serous cystic adenoma.

Abbreviations: CCA, cholangiocarcinoma; GIST, gastrointestinal stromal tumor.

Table 2

Patient demographics and operative data for major robotic pancreatic resections

Characteristic	Value (range)
No. of patients	51
Median age in years (range)	70 (27–85)
Female gender, n (%)	32 (62%)
ASA score ^a II, III, n (%)	21 ASA II, 30 ASA III
Median body mass index (range)	26.4 (19.2–39)
Median operative time, min (range)	560 (327–848)
Median estimated blood loss, mL (range)	300 (50–2000)
Patients transfused, n (%)	12 (22%)
Median length of stay, days (range)	10 (4–87)

^aAmerican Society of Anesthesiologists performance score.

soft glands and normal ducts size reflects the selection bias toward less invasive lesions in this early series. With the exception of the Frey procedures, all pancreatic duct reconstructions employed an end-to-side, duct-to-mucosa technique. The pancreatic remnant was mobilized 1 to 2 cm (PM2) in all cases to facilitate reconstruction. The majority of the RAPD and RACD reconstructions were Type I anastomoses (pancreicojejunostomy) with 2 Type II (pancreicogastrostomy). All patients but one received an internal pancreatic stent to assure patency of the reconstruction: 5F Zimmon stents for Type I ducts (<3 mm) and 7F Zimmon stents for Type II (3–8 mm), and the majority of Type III (>8 mm) ducts.

Postoperative fistula outcomes are presented in Table 4. The overall pancreatic fistula rate was 24% (12/49) as defined by strict International Study Group on Pancreatic Fistula (ISGPF) criteria [17]: 10 out of 42 (21%) in the RAPD

Table 3

ISGPS classification of pancreatic remnant (N = 49)

Pancreatic remnant (n)	ISGPS ^a	Pancreatic texture classification	Duct size (mm)	Remnant mobilization (cm)	ISGPF leak grade
26	IA-PM2	Soft	<3	1–2	A = 5, B = 2, C = 2
1	IB-PM1	Firm	<3	<1	C = 1
1	IB-PM3	Firm	<3	>3	A = 1
5	IIA-PM2	Soft	3–8	1–2	—
2	IIB-PM1	Firm	3–8	<1	—
6	IIB-PM2	Firm	3–8	1–2	A = 2
1	IIIA-PM1	Soft	>8	<1	—
5	IIIB-PM1	Firm	>8	<1	—

Abbreviations: ISGPF, International Study Group on Pancreatic Fistula; ISGPS, International Study Group of Pancreatic Surgery.

^aI = duct size <3 mm, II = duct size 3–8 mm, III = duct size >8 mm; A = soft or normal pancreas, B = firm/hard or fibrotic pancreas; PM1 = pancreatic mobilization <1 cm, PM2 = 1–2 cm, PM3 >2 cm.

Data from Huscher CG, Mingoli A, Sgarzini G, et al. Laparoscopic versus open subtotal gastrectomy for distal gastric cancer: five-year results of a randomized prospective trial. *Ann Surg* 2005;241(2):232–7.

Table 4
Postoperative morbidity and mortality (N = 51)

Operation	Pancreatic fistula	Grade B/C fistula	Clavien ^a complication I/II	Clavien ^a complication III/IV	Clavien ^a complication V
RAPD (42)	10 (24%)	4 (10%)	10 (24 %)	11 (26%)	1
RACP (5)	4 (80%)	1 (20%)	1 (20%)	1 (20%)	0
RATP (2)	NA	NA	0	0	0
RAFP (2)	0	—	0	0	0

Abbreviations: RACP, robotic-assisted central pancreatectomy; RAFP, robotic-assisted Frey procedure with lateral pancreaticojejunostomy; RAPD, robotic-assisted pancreaticoduodenectomy; RATP, robotic-assisted total pancreatectomy.

^aGrade I/II = no organ failure and not necessitating radiologic, endoscopic or operative intervention; Grade III/IV = organ failure and/or necessitating radiologic, endoscopic, or operative intervention; Grade V = death.

group; and 4 out of 5 (80%) in the RACP group. Among the 10 RAPD patients developing pancreatic fistulae, 6 were subclinical (Grade A) and 4 were clinically significant (2 Grade B and 2 Grade C). Of the 3 pancreatic fistulae following RACP, 4 were subclinical (Grade A) and one was clinically significant (Grade C). None of the patients undergoing an RAFP procedure developed a postoperative fistula or complication. Postoperative complications occurring within the first 90 days are presented in Table 4. Clavien Grade III and IV complications occurred in 13 patients (25% of the total study group). Three patients required reoperation due to: postoperative bleeding from the divided stomach [1]; hemorrhage from the GDA stump secondary to a pancreatic leak [1]; and distal bowel obstruction due to an unrecognized Meckel diverticulum leading to biliary anastomotic leak [1]. This patient expired on day 87, due to multisystem organ failure, and is the only mortality in the series (2%). The other 5 complications included sepsis secondary to pancreatic leak (n = 1), bleeding from a GDA pseudoaneurysm in the setting of a pancreatic leak (n = 1), small bowel obstruction and severe delayed gastric emptying presenting 3 weeks after discharge (n = 1), biloma requiring subsequent percutaneous drainage (n = 1), and abdominal abscess requiring interventional radiology drainage (n = 1). Grade I and II complications occurred in 8 patients (27%) and were limited to the RAPD group. These complications included delayed gastric emptying (n = 4), deep venous thromboembolism/pulmonary embolism (n = 2), and wound infection in the right lower quadrant utility incision (n = 2).

The authors evaluated surgical outcomes in their first 20 RAPD procedures and compared them with the second 22 procedures (Table 5). Improvement in perioperative blood loss, risk of pancreatic fistula, and duration of hospital stay was observed between these 2 cohorts. Of interest, the authors observed no reduction in operative times. This finding suggests that the technically demanding portions of the procedure that contribute to morbidity can be mastered in relatively few cases, and raises the possibility that with more experience, outcomes of robotic-assisted pancreatic resection may be better

Table 5
Outcomes in robotic-assisted pancreaticoduodenectomy

Parameters	First 20	Second 22
Conversion	7	1
Operative time (min)	593	536
Median blood loss (mL)	595	300
Pancreatic fistula	5	2
LOS (days)	12.3	9

Abbreviation: LOS, length of hospital stay.

than those following the open approach. The relatively stable operative times likely reflect technological limitations inherent in the current robotic platform (described below).

COMPARISON OF OUTCOMES FOLLOWING ROBOTIC-ASSISTED MAJOR PANCREATIC RESECTIONS WITH SELECTED LAPAROSCOPIC AND OPEN SERIES

The first case report of robotic pancreaticoduodenectomy was made by Giullianoti and colleagues [21] in 2003 as part of a larger series of robotic-assisted general surgery procedures. However, no details regarding the outcomes and approach were included in this initial report. Since that time these investigators have updated that series and reported on the results of 64 major pancreatic resections performed at two different centers (Ospedal Misericordia, Pisa, Italy and University of Illinois, Chicago, IL, USA) [10]. In this series there were 60 RAPD, 3 RACP, and 1 RATP. A majority of the resections were performed for cancer (80%). Among RAPD patients, 19 underwent reconstruction of the pancreatic duct, whereas the remainder had sclerosis of the remnant pancreatic duct. Median operating room time was 421 minutes (range 240–661 minutes) and median blood loss was 394 mL (range 8–1500 mL). The conversion rate was 11%, and 4 patients required reoperations. The overall fistula rate was 31%. For those patients undergoing surgical reconstruction the fistula rate was 4 of 19, or 21%. Other series of RAPD include one by Narula and colleagues [12], who reported the outcomes of 8 cases. Seven of the 8 patients had benign disease, with one cancer. Three (38%) required conversion to open resection. Median operative time was 420 minutes (range 360–500 minutes). There were no reported fistulae or postoperative complications in this small series.

These two early series and the authors' own from the University of Pittsburgh demonstrate that robotic-assisted major robotic resections can be performed with comparable outcomes to open pancreaticoduodenectomy (see Table 5). Like most minimally invasive procedures, the blood loss for minimally invasive pancreaticoduodenectomies appears to be less than open resection, whereas pancreatic fistula rates are slightly higher. The differences in the pancreatic fistula rate between the minimally invasive and open series may be subject to several biases: (1) stringent ISGPF criteria for grading the

pancreatic remnant have only recently been published and widely adopted, accounting for a higher number of asymptomatic fistulae in the more recent minimally invasive series; (2) the minimally invasive series report a higher rate of soft or normal pancreatic remnants, demonstrating selection bias in favor of less technically challenging resections but correspondingly more difficult reconstructions at higher risk of leak; (3) results of small series of minimally invasive major pancreatic resections may represent the learning curve as described for the Pittsburgh experience. Although longer than for open resection, operating times for RAPD are consistent with results at Johns Hopkins in the 1980s and 1990s. It is not unreasonable to assume that with increased familiarity and improved technology with the robotic approach, operating room times may approach those of current open series (Table 6).

LIMITATIONS OF MAJOR PANCREATECTOMY ASSOCIATED WITH THE CURRENT ROBOTIC PLATFORM

Although robotic assistance permits the implementation of time-tested open techniques for major pancreatic resection through a minimally invasive approach, the current platform has several critical limitations. The most significant drawback is the difficulty of operating in multiple quadrants of the abdomen. The size and positioning of the current arms lead to frequent collisions between the arms. The authors have presented here a configuration of ports that allows for minimum arm interference, although future technological innovations may lead to changes in this configuration. This limitation is compounded by the inability to change the position of the table once the robot is docked, preventing gravity from being used as a retractor for the viscera as is commonly done in standard laparoscopic procedures. In the approach presented here the authors use the traditional laparoscopic approach for initial mobilization where assistance of gravity is advantageous. In addition, the authors have found that tacking the end of the divided jejunum and the site of the duodenojejunostomy facilitates identification, making it unnecessary to dock later in the procedure. The lack of tactile feedback is another limitation

Table 6

Comparison of minimally invasive and open major pancreatic resections

Report	n	LOS (days)	OR time (min)	EBL (mL)	Conversion (%)	Pancreatic fistula (%)
Giulianotti et al, [10,21] (robotic)	64	12.5	421	394	11	21 ^a
Pittsburgh group (robotic)	51	10	560	300	10	24
Narula et al, [12] (robotic)	8	9.6	420	NR	37	0
Kendrick and Cusati, [8] (laparoscopic)	62	7	368	240	4.6	18
Crist et al, [5] (JHH open)	573	8	330	700	NR	12

Abbreviations: EBL, estimated blood loss; JHH, Johns Hopkins Hospital; LOS, length of hospital stay; NR, not reported; OR, operating room.

^aFor the 19 patients undergoing pancreatic anastomosis.

of the current platform; this forces the robotic surgeon to use visual cues to judge how much force can be used on tissues. This restraint can be overcome by the surgeon's adoption of visual clues to tension on tissue, blood vessels, and fine suture material. but does require a longer learning curve than traditional open or laparoscopic surgery. Lastly, the cumbersome steps required to exchange surgical instruments disrupts the flow of the operation and leads to longer than necessary operating times. It is likely that future generations of robots will address each of these limitations in the next decade.

EMERGING INNOVATIONS IN ROBOTIC TECHNOLOGY

Several technological innovations are quickly moving toward clinical use that may be readily applicable to major robotic-assisted pancreatic resections. Robotic stapling devices will soon be available, which will be useful in obtaining control of large venous and arterial tributaries and will avoid the need to use the limited access from the assistant port. In addition, the use of real-time integrated imaging in the robotic console will soon be possible, so that the surgeon will be able to use virtual reality scenarios to superimpose the preoperative imaging with the real-time intraoperative views. Lastly, the administration of vital contrast dyes that are visible only under limited spectra of light are being tested in animal models. This approach has the potential to allow the surgeon to identify large vascular structures or potentially the tumor margins by toggling light sources.

SUMMARY

Robotic-assisted major pancreatic resections allow recreation of time-tested open surgical procedures on a minimally invasive platform. Early outcomes from robotic-assisted major pancreatic resections are comparable with those of laparoscopic and open approaches. Robotic assistance has the potential to bring the well-recognized advantages of minimally invasive surgery to major pancreatic resections. Technological innovations and increased surgeon familiarity with this approach will improve, likely leading to greater adoption and acceptance.

References

- [1] Whipple AO, Parsons WB, Mullins CR. Treatment of carcinoma of the ampulla of Vater. *Ann Surg* 1935;102(4):763-79.
- [2] Whipple AO. Pancreaticoduodenectomy for islet carcinoma: a five-year follow-up. *Ann Surg* 1945;121(6):847-52.
- [3] Traverso LW, Longmire WP Jr. Preservation of the pylorus in pancreaticoduodenectomy. *Surg Gynecol Obstet* 1978;146(6):959-62.
- [4] Howard JM. Pancreatico-duodenectomy: forty-one consecutive Whipple resections without an operative mortality. *Ann Surg* 1968;168(4):629-40.
- [5] Crist DW, Sitzmann JV, Cameron JL. Improved hospital morbidity, mortality, and survival after the Whipple procedure. *Ann Surg* 1987;206(3):358-65.
- [6] Winter JM, Cameron JL, Campbell KA, et al. 1423 pancreaticoduodenectomies for pancreatic cancer: a single-institution experience. *J Gastrointest Surg* 2006;10(9):1199-210 [discussion: 1210-91].

- [7] Gagner M, Pomp A. Laparoscopic pylorus-preserving pancreatoduodenectomy. *Surg Endosc* 1994;8(5):408–10.
- [8] Kendrick ML, Cusati D. Total laparoscopic pancreaticoduodenectomy: feasibility and outcome in an early experience. *Arch Surg* 2010;145(1):19–23.
- [9] Palanivelu C, Jani K, Senthilnathan P, et al. Laparoscopic pancreaticoduodenectomy: technique and outcomes. *J Am Coll Surg* 2007;205(2):222–30.
- [10] Giulianotti PC, Sbrana F, Bianco FM, et al. Robot-assisted laparoscopic pancreatic surgery: single-surgeon experience. *Surg Endosc* 2010;24(7):1646–57.
- [11] Zureikat AH, Nguyen KT, Bartlett DL, et al. Robotic-assisted major pancreatic resection and reconstruction. *Arch Surg* 2011;146(3):256–61.
- [12] Narula VK, Mikami DJ, Melvin WS. Robotic and laparoscopic pancreaticoduodenectomy: a hybrid approach. *Pancreas* 2010;39(2):160–4.
- [13] Thomas A, Dajani K, Neoptolemos JP, et al. Adjuvant therapy in pancreatic cancer. *Dig Dis* 2010;28(4–5):684–92.
- [14] Anderson C, Uman G, Pigazzi A. Oncologic outcomes of laparoscopic surgery for rectal cancer: a systematic review and meta-analysis of the literature. *Eur J Surg Oncol* 2008;34(10):1135–42.
- [15] Shuang J, Qi S, Zheng J, et al. A case-control study of laparoscopy-assisted and open distal gastrectomy for advanced gastric cancer. *J Gastrointest Surg* 2011;15(1):57–62.
- [16] Huscher CG, Mingoli A, Sgarzini G, et al. Laparoscopic versus open subtotal gastrectomy for distal gastric cancer: five-year results of a randomized prospective trial. *Ann Surg* 2005;241(2):232–7.
- [17] Gagner M, Palermo M. Laparoscopic Whipple procedure: review of the literature. *J Hepatobiliary Pancreat Surg* 2009;16(6):726–30.
- [18] Milone L, Turner P, Gagner M. Laparoscopic surgery for pancreatic tumors, an uptake. *Minerva Chir* 2004;59(2):165–73.
- [19] Hanly EJ, Talamini MA. Robotic abdominal surgery. *Am J Surg* 2004;188(Suppl 4A):19S–26S.
- [20] Bao P, Potter D, Eisenberg DP, et al. Validation of a prediction rule to maximize curative (R0) resection of early-stage pancreatic adenocarcinoma. *HPB (Oxford)* 2009;11(7):606–11.
- [21] Giulianotti PC, Coratti A, Angelini M, et al. Robotics in general surgery: personal experience in a large community hospital. *Arch Surg* 2003;138(7):777–84.