

Anesthetic Management in Upper Extremity Transplantation: The Pittsburgh Experience

R. Scott Lang, MD,* Vijay S. Gorantla, MD, PhD,† Stephen Esper, MD, MBA,* Mario Montoya, MD,* Joseph E. Losee, MD, FACS, FAAP,‡ Ibtesam A. Hilmi, MB, ChB, FRCA,* Tetsuro Sakai, MD, PhD,* W. P. Andrew Lee, MD,§ Jay S. Raval, MD,|| Joseph E. Kiss, MD,|| Jaimie T. Shores, MD,§ Gerald Brandacher, MD,§ and Raymond M. Planinsic, MD*

BACKGROUND: Hand/forearm/arm transplants are vascularized composite allografts, which, unlike solid organs, are composed of multiple tissues including skin, muscle, tendons, vessels, nerves, lymph nodes, bone, and bone marrow. Over the past decade, 26 upper extremity transplantations were performed in the United States. The University of Pittsburgh Medical Center has the largest single center experience with 8 hand/forearm transplantations performed in 5 recipients between January 2008 and September 2010. Anesthetic management in the emerging field of upper extremity transplants must address protocol and procedure-specific considerations related to the role of regional blocks, effects of immunosuppressive drugs during transplant surgery, fluid and hemodynamic management in the microsurgical setting, and rigorous intraoperative monitoring during these often protracted procedures.

METHODS: For the first time, we outline salient aspects of upper extremity transplant anesthesia based on our experience with 5 patients. We highlight the importance of minimizing intraoperative vasopressors and improving fluid management and blood product use.

RESULTS: Our approach reduced the incidence of perioperative bleeding requiring re-exploration or hemostasis and shortened in-hospital and intensive care unit stay. Functional, immunologic and graft survival outcomes have been highly encouraging in all patients.

CONCLUSIONS: Further experience is required for validation or standardization of specific anesthetic protocols. Meanwhile, our recommendations are intended as pertinent guidelines for centers performing these novel procedures. (Anesth Analg 2012;X:●●●—●●●)

Reconstructive transplantation is an emerging multidisciplinary specialty that integrates the principles of plastic surgery with those of transplantation surgery. Transplantation of the upper extremity, craniofacial tissue, vascularized joint, abdominal wall, larynx, and trachea is now a clinical reality.¹ The first lower extremity transplantation was credited to the Patron Saints Cosmas and Damien, circa 300 AD. Early attempts at hand transplantation in 1964 by the Ecuadorean surgeon, Roberto Gilbert, failed because of primitive immunosuppression

and lack of an understanding of the immunology of vascularized composite allografts (VCA). In 1998, the Lyon team performed a hand transplant under conventional triple drug immunosuppression, heralding the modern era of clinical VCA.¹⁻³ Support for this reconstructive modality has since grown despite concerns for the long-term side effects of immunosuppression as well as acute and chronic rejection.^{4,5} Between September 1998 to November 2011, >80 upper extremity transplants were performed (Fig. 1). Currently, 7 centers perform the procedure in the United States (Table 1).

Our group and other teams have published extensively on the immunologic and surgical aspects of upper extremity transplantation.⁶⁻¹⁰ However, there are no published studies on anesthetic management in this novel and emerging niche specialty. We present for the first time, challenges and considerations in upper extremity transplant anesthesia based on experience at one of the few nation's reconstructive transplant centers. Anesthetic management and techniques were optimized in concordance with improvements in procedural, patient, and protocol-related issues by the surgical team. The Pittsburgh Upper Extremity Transplant Anesthesiology Protocol (PUETAP) offers important guidelines and recommendations for management of upper extremity transplant recipients.

From the *Department of Anesthesiology and †Department of Surgery, University of Pittsburgh Medical Center, Pittsburgh, PA; ‡Department of Surgery, Children's Hospital of Pittsburgh, Pittsburgh, Pennsylvania; §Department of Plastic and Reconstructive Surgery, Johns Hopkins University School of Medicine, Baltimore, MD; and ||The Institute for Transfusion Medicine University of Pittsburgh Medical Center, Pittsburgh, PA.

Accepted for publication April 12, 2012.

The Pittsburgh Upper Extremity Transplantation Program was funded in part by the Armed Forces Institute for Regenerative Medicine [Award W81XWH-08-2-0032], the Orthopedic Extremity Trauma Research Program [Award W81XWH-08-1-0421], and generous intramural support by the University of Pittsburgh Medical Center.

This report was previously presented, in part, at the American Society of Anesthesiologists, Association of University Anesthesiologists.

R. Scott Lang and Vijay S. Gorantla are co-first authors.

The authors declare no conflicts of interest.

Reprints will not be available from the authors.

Address correspondence to Raymond M. Planinsic, MD, University of Pittsburgh Medical Center Department of Anesthesiology, 200 Lothrop Street, Suite C-200 Pittsburgh, PA 15213. Address e-mail to planinsicrm@anes.upmc.edu.

Copyright © 2012 International Anesthesia Research Society
DOI: 10.1213/ANE.0b013e31825da401

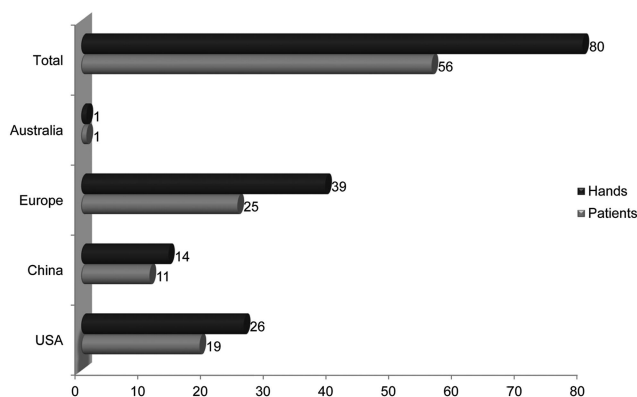


Figure 1. Worldwide experience in upper extremity transplantation. The total number of upper extremity transplants (dark bars) and recipients (light bars) are shown for the United States, China, Europe, and Australia.

potential large volume blood product transfusions, frequent metabolic and coagulation monitoring (Fig. 2), and adequate intraoperative and postoperative analgesia to facilitate successful transplantation.

Fluid Management

Our protocol recommends IV (internal jugular) access via a large bore (Cordis or Shiley) catheter. Central venous pressure monitoring is via a single-lumen infusion catheter inserted through the diaphragm of the introducer for unilateral transplant (UHT). The 9-gauge introducer has a large-bore side port for rapid fluid and blood product infusion and a smaller side port for medications. An additional 14-gauge IV catheter is recommended in the nonoperative arm for a UHT. Bilateral hand transplant recipients have limited upper extremity IV access requiring an additional 7-gauge double lumen central venous catheter in the internal jugular vein. Central venous pressure is used to help assess adequacy of fluid management. We recommend placement of a 20-gauge radial artery cannula in the nonoperative arm for UHT and an 18-gauge femoral artery cannula for bilateral hand transplant recipients. Having 2 arterial catheters may be prudent considering the length of these procedures and the possibility of intraoperative loss of arterial tracing. Transesophageal echocardiography and a rapid infusion system (RIS) or a fluid management system must be available before the start of the procedure. Temporary deflation of tourniquets after arterial anastomoses is an important step to washout K^+ via venous egress of Custodiol from the graft. Major blood loss must be anticipated at this time as well as during the release of microvascular clamps when the maximum allowable ischemic time has been reached. The PUETAP follows the trauma resuscitation protocol of 1 U packed red blood cells (PRBC): 1 U fresh frozen plasma (FFP): 250 cc normal saline.¹¹ This ratio achieves a hematocrit of 26%–28% in the RIS reservoir. The blood bank must assure availability of 10 U of PRBC and 10 U of FFP for every procedure. Platelets should also be available to prepare for excessive surgical bleeding or thrombocytopenia. A fluid warmer is used for the infusion of cold solutions. An increase in ambient room temperature, use of forced air warmers, and extensive surgical draping help maintain body temperature throughout the procedure. We recommend that α agonists be avoided as they may affect graft perfusion. Dopamine is

instituted when hypotension is not adequately corrected by infusion of IV fluids or blood products, such as vasodilation in response to donor extremity reperfusion. Low-dose dopamine maintains regional bloodflow by increasing cardiac contractility through β -1 agonist effects and sustains renal perfusion via dopaminergic receptors.

Intraoperative Monitoring

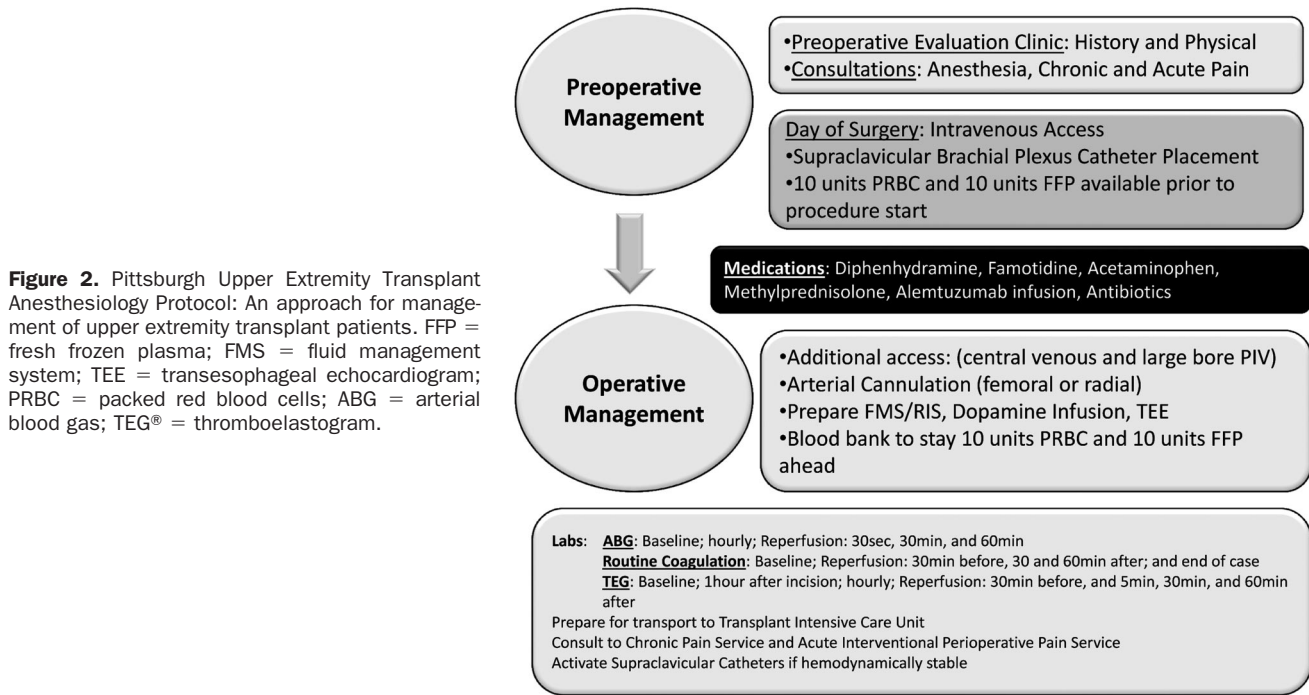
Our protocol recommends monitoring of arterial blood gases (ABG), sodium, potassium, calcium, glucose, lactate, hemoglobin, and serum osmolality during surgery in all patients. ABGs are documented at baseline and hourly. Additionally, after reperfusion of the transplant, 30-second, 30-minute, and 60-minute ABGs are determined along with the above laboratory values. These time points are defined to help assess peak potassium concentrations as well as other immediate metabolic and physiologic changes associated with reperfusion. Routine coagulation panels including a prothrombin time, partial thromboplastin time, international normalized ratio, platelets, and fibrinogen are performed at baseline, 30 minutes before reperfusion, and 30 and 60 minutes after reperfusion. A final coagulation panel is performed at completion of transplantation. A thromboelastogram (TEG[®], Haemonetics, Braintree, MA) is also monitored at regular intervals: at baseline, 60 minutes after incision, and then hourly until surgical completion. Additional TEG[®]s are evaluated 30 minutes before reperfusion, 5 minutes, 30 minutes, and 60 minutes after reperfusion. The 3 TEG[®]s studied after reperfusion (5-minute, 30-minute, and 60-minute) should include natural, amicar, and protamine channels to exclude coagulopathy related to possible fibrinolysis or heparin from the donor graft. Though a completed TEG[®] takes up to 30 minutes for completion, important information, such as reaction time, angle, and maximum amplitude, can be obtained much sooner by seeing the progressive readout on TEG[®] monitors in the operating room. Calcium gluconate is used to correct for decreases in ionized calcium noted on ABG and/or after large volume blood transfusion with a noticeable decrease in contractility seen on transesophageal echocardiography or arterial line tracing. Base deficits >7 or pH <7.2 must be corrected with sodium bicarbonate.

Regional Anesthesia Strategies

Our protocol recommends ultrasound-guided preoperative placement of supraclavicular brachial plexus nerve blocks unilaterally or bilaterally depending on the surgical site. Supraclavicular access is a useful route for brachial plexus blockade and securing indwelling catheters. A single bolus of a short-acting local anesthetic is used during catheter placement to confirm function of the block as well as provide analgesia for initial tourniquet inflation. However, it is not activated for postoperative analgesia and vasodilation by continuous infusion until completion of the transplant. This approach avoids the potential contribution of upper extremity vasodilation to brisk bleeding and hypotension when the surgical tourniquet is deflated during surgery as described under fluid management.^{12,13} After the initial bolus has worn off, an opioid general

Table 1. Upper Extremity Transplantation in the United States

Transplants	University of Pittsburgh Medical Center (Pittsburgh)	Jewish Hospital (Louisville)	Wilford Hall Air Force Base (San Antonio)	University of California Los Angeles	Emory University (Atlanta)	University of Pennsylvania Health (Philadelphia)	Brigham & Women's Hospital (Boston)	Total
Unilateral	2	7	1	1	1	0	0	12
Bilateral	3	1	0	0	0	1	2	7
Male	3	8	0	0	0	0	1	12
Female	2	0	1	1	1	1	1	7
Graft losses	0	1	0	0	0	0	2	3



anesthetic helps patient tolerance of the tourniquet. Post-operative analgesia, provided by regional anesthetics, also helps diminish stress responses secondary to pain, such as pain during early physical therapy.¹⁴

METHODS

Study Design

This was a nonrandomized study. There were no true controls (nontreated/placebo or with conventional multi-drug immunosuppression) and no true independent variables. The University of Pittsburgh IRB (PRO07030180) and the Department of Defense Human Research Protection Office (A-14,731) approved the study (listed on <http://clinicaltrials.gov>; NCT00722280). The patients enrolled in the study provided written consent to scientific publication of their research-related outcomes.

Donor and Recipient Selection

Donor Selection Criteria

The hand transplant team selected brain-dead donors through their designated organ procurement organization. The mandatory requirements were family consent for limb donation, stable donor (does not require excessive vasopressors to maintain arterial blood pressure), age between 18 to 65

years, limb matched for size with recipient, same blood type as recipient, negative cross-match, and, importantly, accurate matching for gender, skin tone, and race (may be relative requirement depending on recipient consent). Human leukocyte antigen (HLA) matching was not performed. Donors were excluded in untreated sepsis, human immunodeficiency virus (HIV) (active or seropositive), active tuberculosis, hepatitis B or C, viral encephalitis, toxoplasmosis, malignancy, current/recent IV drug abuse, tattoo on the potential transplant, paralysis of ischemic or traumatic origin, any peripheral neuropathy, severe limb-deforming rheumatoid or osteoarthritis, or mixed connective tissue disease. Recipient selection criteria included (1) age (>18 years <65 years); (2) no serious coexisting medical (coronary artery disease, diabetes) or psychosocial problems (including alcoholism, drug abuse); (3) negative history for malignancy (for 10 years) or HIV (at transplant); (4) negative cross-match with donor; (5) negative pregnancy test in female recipient of child-bearing potential and consent to use reliable contraception for at least 1 year after transplantation; (6) amputation may be recent (<1 year, wound healing complete) or remote (patient preferably should have undergone rehabilitation with or without

prostheses); (7) level of amputation may be above or below the elbow; and (8) thorough psychologic screening for assessment of posttraumatic stress disorder, quality of life, level of acceptance of the injury, and compliance with rehabilitation and drug treatment after transplantation was required for patient candidacy.

The Pittsburgh Immunomodulatory Protocol

Recipient leukocytes were collected by leukapheresis from each listed recipient at the time of listing and cryopreserved. Upon identification of an appropriate donor, prospective recipients were treated before upper extremity transplant (day 0) with a single dose of alemtuzumab (Campath 1H[®], Millennium Pharmaceuticals, NJ), 30 mg IV, to initiate lymphocyte depletion. Diphenhydramine (Benadryl[®]) 50 mg IV and methylprednisolone were given at a dose of 500 mg IV 1 hour before alemtuzumab and then postoperatively on day 1 at a dose of 250 mg IV and on postoperative day (POD) 2 at a dose of 125 mg. Premedication also included famotidine, acetaminophen, and cephalexin at 1 to 2 g given IV preoperatively. Daily tacrolimus monotherapy (0.2 mg/kg/day) was commenced (Prograf, Astellas, Japan). Dimethylsulfoxide-cryopreserved unmodified donor bone marrow cells were thawed and infused on POD 10 to 14 (dose range: 50 to 100 × 10⁶ mononuclear cells/kg body weight). Daily tacrolimus was continued as monotherapy until 12 months after transplantation. Any episodes of early acute rejection were first treated with topical tacrolimus and/or clobetasol before increasing maintenance dosing.

Upper Extremity Transplantation

Donor Procedure

Limb dissection was begun before cross-clamping of the aorta and before organ retrieval. Limbs were perfused under isolated tourniquet by cold Histidine-Tryptophan-Ketoglutarate (HTK, Custodiol, Essential Pharmaceuticals, Newton, PA) solution through a brachial artery cannula before disarticulation. Upon completion of retrieval, the donor body was fitted with a cosmetic prosthesis, allowing the family the option of an open-casket funeral. After retrieval, the limb (wrapped in moist sterile gauze and placed in a polyurethane bag) was transported in a sterile container (provided by the organ procurement organization) with iced water at 4°C to 6°C. As we described earlier,^{15,16} donor vertebral bodies Th8-L4 were excised and preserved with HTK supplemented with gentamicin (50 µg/mL) and processed under current good manufacturing practice conditions. Bone fragments were crushed and fragments resuspended in medium and tumbled twice. Cells were pooled, filtered, and cryopreserved in liquid nitrogen until infusion.

Recipient Procedure

Recipients were positioned supine and the amputated stump explored under axillary block or general anesthesia. Fasciotomies were done before rigid fixation and before reperfusion with a shunt. We have previously described the technique of upper extremity transplantation.^{9,10} A 2-team approach was used. The donor team prepared the donor limb on the back table, tailoring the forearm to the needs of

the recipient. Each recipient extremity required 1 main transplant surgeon and 1 assistant transplant surgeon (another dissecting the donor limb). One scrub nurse, 2 circulators, and at least 1 anesthesiologist were needed. Tissue requirements from the donor were identified based on preoperative assessment of the recipient and the recipient team must have clearly identified the amount of nerve, artery, and veins required from the donor for transplantation. The sequence of tissue repair is to minimize ischemia time and includes bony fixation → artery repair → vein repair (revascularization) → tendon repair → nerve repair. Intraoperative biopsies are taken of all tissues and bone marrow to serve as baseline controls.

Assessment for Rejection and Graft Versus Host Disease (GVHD)

Graft-skin biopsies were routinely performed on days 0, 7, 14, 21, and 30 and monthly thereafter until the first year plus whenever clinically indicated (visible signs of rejection such as a maculopapular rash). Grading biopsy samples were analyzed by histology and immunohistochemistry (staining for CD3, CD4, CD8, CD20, and CD68) for quantification and characterization of a potential cellular infiltrate. Scoring for severity of acute rejection was per the Banff classification.^{17,18} Important clinical characteristics of acute rejection included edema, erythema, escharification, and necrosis. Biopsies were examined for evidence of chronic rejection including intimal hyperplasia and subintimal foamy histiocytes in the vessels of the skin or muscle and tissue fibrosis. GVHD is a rare adverse effect after unrelated donor bone marrow infusion (DBMI), wherein T cells from the donor graft attack the recipient and initiate a systemic immune reaction. Clinical diagnosis of GVHD is based on previously described criteria.¹⁹

Immune Monitoring

Recipient and donor cells were typed for HLA antigens pretransplant but HLA matching was not performed. All sera were screened by ELISA (to identify IgG anti-HLA Class I- and Class II-specific antibodies independently) and by Luminex[®] assay. Fluorescence activated cell sorting and polymerase chain reaction (PCR) analysis was used for detection of micro- or macrochimerism in recipients. Cell-mediated immunity was measured by the ImmuKnow[®] (Cylex Incorporated, Columbia, MD) assay that detects adenosine triphosphate synthesis in CD4 cells.

Rehabilitation Regimen

Once the viability of the transplanted limb is guaranteed, the focus of rehabilitation is the restoration of function including the ability to perform physical, psychosocial, vocational, and recreational activities.²⁰ Passive range of motion (ROM) exercises were cautiously initiated within 24 to 48 hours. This reduced edema and stiffness, as well as prevention of claw deformity. At 1 week after transplantation, recipients were encouraged cautiously to initiate active mobilization of the transplanted hand with finger movements. Special splints (e.g., dynamic extension splints) and casting and bracing were used to appropriately position the hand and allow for initiation of exercise. The wrist

was positioned in slight extension; the metacarpophalangeal joints in 50 to 70 degrees of flexion; the interphalangeal joints held at 0 degrees and the thumb was held in a balance between radial and palmar abduction (by light dynamic extension). Approximately 4 to 5 weeks postsurgery, depending upon bony healing, wrist and forearm ROM was initiated within a hand-based anticlave splint. From 8 to 12 weeks postsurgery, biofeedback training and cognitive therapy were added depending upon the level of healing and usage gained at that time. At 12 weeks postsurgery, a dynamic wrist extension splint was applied by connecting it to the anticlave splint. This aids in strengthening of the wrist flexors and extensors by allowing wrist flexion against resistance and assistive active extension. This splint is used 3 to 4 times a day for 15 to 30 minutes and strengthens the repaired tendons and muscles by increasing flexor strength and balancing the antagonistic muscle groups. Promoting protected early active motion and blocking metacarpophalangeal joint extension helped achieve "intrinsic-plus" posture and coordinated grasping.

Standard Functional Outcome Tests

Standard functional outcome tests included those tests used by hand transplant teams around the world.

Motor Return

The Carroll test was used to measure the patients' ability to perform specific arm and hand activities of a general nature during ordinary daily living.²¹ Grip strength, pinch strength, and ROM were measured. In addition, the Disability of Arm, Shoulder and Hand questionnaire was completed when listing the patient and at yearly intervals after surgery. The overall functional outcome was analyzed in a standardized way using the IRHCTT Registry Functional Score System that is in use at hand transplant centers worldwide.²²

Sensory Return

Tinel's sign was assessed until it advanced to the fingertips. Thereafter, Semmes Weinstein monofilament testing (for pressure threshold of slowly adapting receptors), vibration (30 cps and 250 cps), and Weber static and Dellon moving 2-point discrimination (for number of innervated receptors) were performed. Electrophysiological studies were also done.

Data Collection and Outcome Measures

Multiple factors (such as higher level of amputation, rehabilitation regimen, medication compliance, etc.) could impact graft outcome (functional return and graft rejection risk) after hand transplantation. Adverse effects were documented qualitatively (e.g., histopathologic grading of rejection) and quantitatively (e.g., monitoring of kidney and liver function, glucose metabolism, infectious disease titers, etc.). The number and severity of side effects were documented and analyzed in relation to pharmacokinetic and pharmacodynamic data (of immunosuppression). Efficacy-related outcomes were summarized by number and proportion of patients with biopsy-proven rejection, number and proportion with 0, 1, 2, 3, or more biopsy-proven rejection episodes, number and proportion losing their graft, and number and proportion of patients administered

Table 2. Patient Demographics

Patient	Age	Sex	Site	Mechanism of injury	Comorbidities
1	24	Male	Right	Blast	None
2	57	Male	Bilateral	Sepsis	HTN, HLP, GERD
3	41	Male	Bilateral ^a	Trauma	HTN
4	27	Female	Right	Sepsis	None
5	33	Female	Bilateral	Sepsis	None

All preoperative coagulation studies were normal for each patient.

HTN = hypertension; HLP = hyperlipidemia; GERD = gastroesophageal reflux disease.

^a Transplant left hand and right forearm (including elbow joint) and hand.

1 or more courses of immunosuppression for treatment of rejection (bolus steroids, antithymocyte globulin, Campath 1H, or any other medication beyond the standard protocol). Functional and clinical outcomes were correlated with quality of life data. The criterion for success for this protocol was upper extremity transplant survival under reduced immunosuppression (as compared to the historical cohort on high-dose/multidrug therapy) with return of function comparable to that achieved under conventional immunosuppression in the historical cohort.

Patients

Eight hand/forearm transplants were performed in 5 recipients over a 2-year period at the University of Pittsburgh Medical Center (Pittsburgh, PA) (Table 2). A formal anesthetic management protocol was not followed for the first 2 patients. After the first 2 transplants, the Transplant and Liver Anesthesia team reviewed this early experience to determine specific challenges and areas for improvement with particular emphasis on timely notification of potential massive transfusion needs to the blood bank. An anesthetic protocol was subsequently developed to address these issues. An overview of the anesthetic management discussing specific patient or procedural issues is presented for 2 patients to highlight the pre- (Patient 2) and post- (Patient 5) PUETAP development and patient outcomes. Both patients underwent bilateral upper extremity transplantation.

Patient 2 (Bilateral Hand Transplant/Pre-PUETAP Development)

A 57-year-old man with quadrimembral amputations²³ (secondary to pressor-induced ischemic injury after streptococcal sepsis in 1999) became the first bilateral upper extremity transplant recipient in the US on May 4, 2009.

His pertinent past medical history included hypertension, hyperlipidemia, and gastroesophageal reflux disorder. A preoperative nuclear stress test revealed an ejection fraction of 75% with a low probability of ischemia and normal ventricular wall motion. His home medications included triamterene/hydrochlorothiazide, lisinopril, atenolol, loratidine, nexium, and aspirin.

In the preoperative area, central venous access via the right internal jugular was obtained and bilateral ultrasound-guided supraclavicular catheters were inserted and tested with a bolus of local anesthetics. Premedication (including anxiolytics and pain medications) and induction immunosuppression (alemtuzumab) were administered.

A goal mean arterial blood pressure was set for this patient at 65 mm Hg. This required a dopamine infusion up to

T2

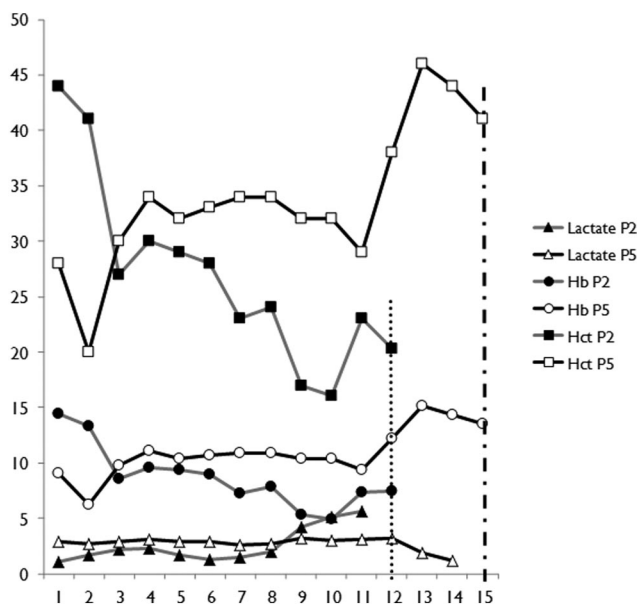


Figure 3. Lactate, Hemoglobin, and Hematocrit Trends for Patients 2 and 5. The lactate levels throughout the operation are shown for Patient 2 (P2, light grey) and Patient 5 (P5, black) as arrows. The hemoglobin (Hb) levels during the procedure are shown for Patient 2 and Patient 5 as lines with diamonds. The hematocrit (Hct) levels throughout the operation are shown for Patient 2 and Patient 5 as lines with circles. The hashed lines represent end-of-surgery times (small hashes - P2 and large hashes - P5).

a dose of 7 mcg/kg/minutes for a total duration of 7.5 hours. Crystalloid and colloid solutions were used throughout the procedure. Intraoperatively, hemoglobin levels decreased to 4.9 mg/dL, with lactate levels increasing to 6 to 8 mEq/L and a base deficit maximum of -10 mEq/L. Trends of intraoperative lactate, hemoglobin, and hematocrit levels are depicted in Figure 3. Blood product administration did not occur until 3 hours after incision when a significant decrease in hemoglobin was noted. Calcium and sodium bicarbonate were also used intraoperatively. Intraoperative data are displayed in Table 3.

Approximately 6 hours into the procedure, the patient developed significant coagulopathy evidenced by excessive intraoperative bleeding and corresponding laboratory values. Coagulopathy continued into the perioperative period, and emergency re-exploration was required 4 hours and 46 minutes after the transplant. He also required vacuum-dressing placement and skin grafting. During his hospitalization, his surgical wounds healed and functionality improved, despite transient deconditioning necessitating prolonged inpatient rehabilitation for ambulation.²³ Postoperatively, pain was controlled via supraclavicular nerve blocks, nurse-controlled analgesia, and patient-controlled analgesia. A summary of postoperative hospital duration of stay is shown in Table 4.

Patient 5 (Bilateral Hand Transplant/ Post-PUETAP Development)

A 33-year-old woman with quadrimembral amputations (secondary to ischemic gangrene after meningococcal septicemia and multisystem organ failure in 2003) became the first female bilateral upper extremity transplant recipient in the US on September 18, 2010.

Her pertinent medical history included multiple salvage and reconstructive surgeries related to amputations, muscle and skin grafts, and laparoscopic salpingectomies for ectopic pregnancies. Her home medications included acyclovir, multivitamins, and naproxen.

Preoperative preparation and premedication were similar to that described in patient 2. Five hours into the procedure, the hemoglobin level was 9 mg/dL. The RIS was initiated per the PUETAP in anticipation of ongoing blood loss. Blood products were infused at rates from 500 to 1000 cc/hour. As blood loss became more brisk, the RIS rate was increased to 1000 to 2000 cc/hour. Seven hours into the procedure, the patient developed hypotension poorly responsive to fluid resuscitation. Her blood pressure was stabilized with dopamine given at a maximum dose of 2 mcg/kg/minutes for 3 hours. Her mean arterial blood pressure was stable ranging between 65 to 70 mm Hg for most of the surgery with a urine output of 150 to 250 cc/hour. Lactate increased to a high of 5.1 mEq/L with the base deficit varying between -2 and 7 mEq/L. Importantly, hemoglobin was kept above 8 mg/dL throughout the procedure. Trends of intraoperative lactate, hemoglobin, and hematocrit levels are depicted in Figure 3. Of note, blood loss for this case was significant, requiring 20,000 mL of RIS infusate. TEG[®]s were taken at the designated times.

A selection of intraoperative TEG[®]s is shown in Figure 4 to demonstrate alterations that were encountered. Intraoperative data are displayed in Table 3. No clinically significant coagulopathy occurred during or after surgery. Despite the large volume of blood loss and the potential for third space fluid shifts, the patient remained stable. The patient developed hematomas in one of the transplants on POD 21 and 22 because of superficial venous bleeders requiring surgical drainage and ligation. Postoperative analgesia was achieved as in patient 2. Functionality improved in both hands as she continued to recover. Postoperative data are summarized in Table 4.

DISCUSSION

The PUETAP as described was developed, improved, and optimized from the nation's largest cumulative single-center experience with upper extremity transplants. Procedural and protocol-related pitfalls and issues were identified, and solutions were implemented in the areas of IV access, fluid management, intraoperative hemodynamic and invasive vascular monitoring, and regional anesthesia facilitating trends that positively impacted intraoperative management and surgical outcome. As in any other transplant protocol, it is important to consider the effects, interactions, and impact of immunosuppressive regimen and associated interventions during donor and recipient preparation. Agents such as alemtuzumab and tacrolimus used in recipient treatment, as well as preservation media such as HTK (Custodiol[®], Essential Pharmaceuticals) used in the donor allograft retrieval, could impact anesthetic management upper extremity transplant recipients. Coagulopathy after infusion of alemtuzumab is an important complication that has been reported in the solid organ literature and requires careful consideration in VCA recipients.²⁴ Other side effects include hypotension, pulmonary edema, and allergic (anaphylactic) reactions. Upper

F4

Table 3. Intraoperative Data

Patient	Duration of procedure	RIS	PRBC	FFP	Platelets	Cryo	Crystalloid (cc)	Colloid (cc)	Urine output (cc)	Donor limb ischemic time (h)	Dopamine total infusion dose (mg)
1	11 h, 53 min	None	6	2	0	0	10500	2500	5000	Not recorded	236.28
2	9 h, 22 min	None	19	4	1	0	12000	7000	585	Right: 7; left: 7	238.71
3	11 h, 36 min	11000	15	9	0	0	6000	3250	2000	Right: 6.5; left: 10	59.67
4	12 h, 35 min	5000	7	5	0	0	4000	2500	3400	9	97.2
5	12 h, 17 min	20441	33	34	3	2	5200	500	2350	Right: 8.5; left: 10.5	13.77

RIS = rapid infusion system; PRBC = packed red blood cells (units); FFP = fresh frozen plasma; Platelets = pools of platelets; Cryo = cryoprecipitate (units).

Table 4. Inpatient Hospitalization

Patient	Total inpatient stay	ICU stay	Discharge
1	26	9	Home
2	65	24	AIRU
3	56	8	Family house
4	35	3	Family house
5	52	10	Family house

ICU = intensive care unit; AIRU = acute inpatient rehabilitative unit. Family house is a local facility that houses transplant patients and their families to enable outpatient treatments.

extremity transplantation is a technically and logistically complicated procedure that can last from 10 to 15 hours. Thus, in addition to medication-related complications, there is potential for significant blood loss, reperfusion injury, microvascular effects of regional blockade and sympathetic denervation, coagulopathy, and complications related to fluid management.²⁵ The overriding goals are to ensure effective anesthesia and analgesia, reduce vasopressor use and vasospasm, avoid hypotension, improve oxygenation, and optimize graft function.²⁶

The success of the PUETAP required the anesthesiologists to become true perioperative physicians. Given the complexity of these cases, we recommend that transplant anesthesiologists meet with every listed recipient before surgery to clarify the anesthetic procedure and plan, as well as allay any patient concerns for this major surgery. The patient must also have the option to meet with a member of the Acute Interventional Perioperative Pain Service to discuss the use of regional anesthesia and expectations for pain control immediately after the procedure. Chronic pain specialists should be consulted postoperatively to ensure adequate pain control during the prolonged recovery. They may also be available during the preoperative evaluation if requested.

The PUETAP recommends that patients have supraclavicular catheters placed using a bolus of local anesthetic before induction of general anesthesia. Though upper extremity transplantation may be possible with IV opioids and a general anesthetic, regional anesthesia provides significant advantages not only for analgesia, but also for overall graft survival.²⁷ Brachial plexus blocks have been shown to cause significant venous dilation, perhaps due to a sympathectomy-like effect.²⁸ This sympathectomy has also been implicated in diminishing the sympathetically driven development of postoperative hypercoagulability.²⁵ The supraclavicular brachial plexus block also provides rapid onset with a prolonged duration. Specific targeting of the musculocutaneous nerve and medial cutaneous nerve

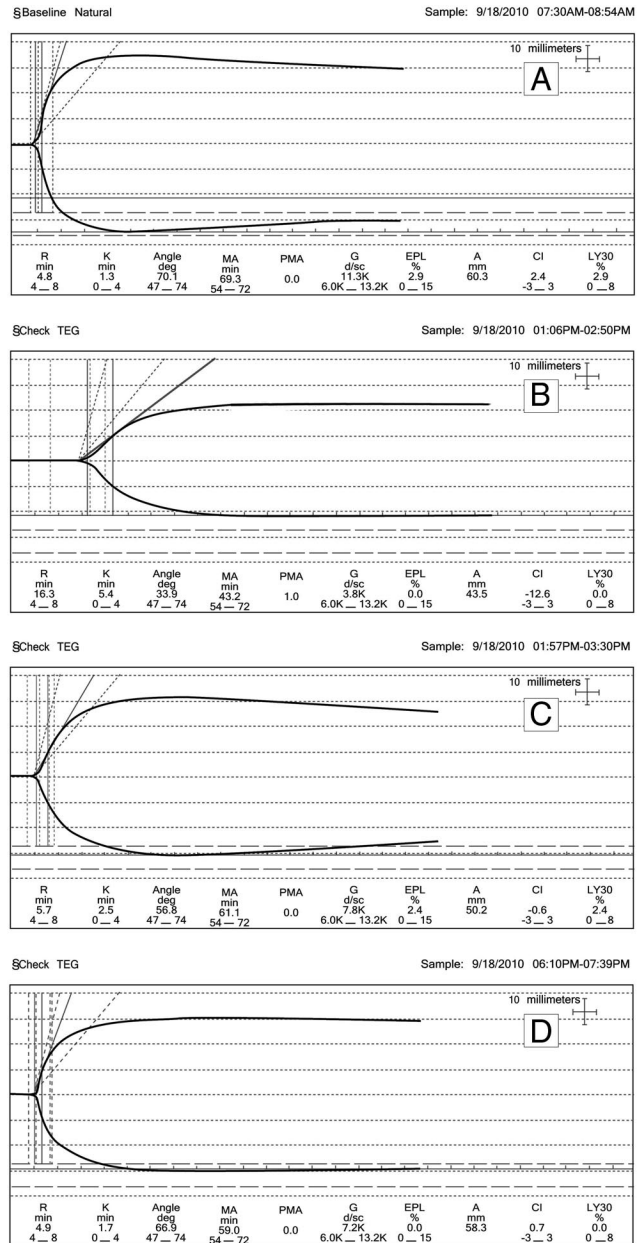


Figure 4. Thromboelastograms for Patient 5. (A) Baseline, before surgical incision. (B) TEG[®] after reperfusion of right extremity. (C) TEG[®] after correction with rapid infusion system (RIS) balanced infusate of PRBC, FFP, and Crystalloid (D) Final TEG[®], before surgical end time. TEG[®]: thromboelastogram. PRBC: packed red blood cells. FFP: fresh frozen plasma.

of the forearm allow the use of tourniquets intraoperatively. Ultrasound guidance has been shown to improve accuracy of catheter introduction, decrease patient discomfort, accelerate block onset, decrease local anesthetic dose, and provide a more complete block. However, a muscle twitch response to nerve stimulation may not occur.²⁹ We realize that other regional anesthetic techniques may be used successfully for upper extremity transplantation. Techniques such as the infraclavicular brachial plexus blockade may serve as useful alternatives to the supraclavicular technique. We have extensive experience with bilateral supraclavicular blocks with no noted complications. The preference for an infraclavicular approach is team-dependent and avoids the risk of phrenic nerve injury or pneumothorax with the supraclavicular approach. We did not quantify pain scores as regional anesthetics were used for all patients and we were limited by lack of controls for comparison. Chronic pain medications such as gabapentin or pregabalin are not currently used in the PUETAP but may be of some benefit in patients who develop chronic pain. As patient follow-up continues, rates of chronic pain can be further assessed. To our knowledge, there is no literature addressing the relationship between regional anesthesia and graft survival after upper extremity transplantation. Evidence supporting regional anesthesia has been extrapolated from literature in other reperfusion scenarios such as in upper extremity replantation.²⁵

Proper monitoring for adequacy of hemostasis and hemodynamic status is critical in upper extremity transplantation. Precise arterial blood pressure monitoring through an arterial catheter is advisable, because large fluid shifts, hemodynamic instability and metabolic abnormalities are possible during these long procedures. In our experience, though tourniquet use reduced surgical bleeding in many cases, transplant perfusion and ischemia-specific considerations mandated the release of pressure periodically in addition to other periods of tourniquet deflation. The PUETAP advocates the use of a preprimed RIS in anticipation of significant bleeding that may or may not be complicated by coagulopathic issues. Although rare, extensive surgery and immunologic responses such as transfusion reactions or transplant rejection can predispose a patient to disseminated intravascular coagulation.³⁰ The use of arterial lines in donor extremities before transplant increases the risk of vascular thrombosis and intra- or perioperative graft failure.³¹ Other coagulopathies may also become evident, such as dilutional coagulopathies or those rarely caused by drugs such as alemtuzumab.²⁴ In our experience, no patient experienced significant adverse events directly related to the immunosuppressive medications.^{1,2} The diagnosis and management of coagulopathy can be challenging especially if the etiology is complex or obscure. An example is the presence of preexisting anti-heparin antibodies in a donor reported in face transplantation.³² In this case, the anesthesia team was involved in early planning including donor selection with detailed access to the donor's medical history. This enabled alternative anticoagulation for the donor and recipient with bivalirudin avoiding a possible complication of heparin-induced thrombocytopenia. The team also relied on a full hypercoagulation workup including the use of a serotonin release

Table 5. Coagulation Profiles

Patient	PT	PTT	INR	Platelets	Baseline platelets	Fibrinogen	Hg
1	26.6	57.6	2.3	99	275	Not recorded	6.9
2	66	>200	7.3	33	171	31	4.9
3	21.7	80.6	1.8	82	241	139	6.2
4	21.6	44.9	1.8	92	168	130	7.8
5	20.3	51.5	1.7	99	227	167	7

Most abnormal values recorded intraoperatively.

PT = prothrombin time; PTT = partial thromboplastin time; INR = international normalized ratio.

assay.³³ Catecholamines associated with surgical stress and pain responses can increase platelet aggregation, thus increasing the risk of postoperative graft thrombosis.³⁴ TEG[®] provides information that may not be evident on routine coagulation panels (Table 5) and is one of the most sensitive methods for detecting postoperative complications related to coagulopathy.³⁵ TEG[®] evidence of increased platelet-fibrinogen interactions has been associated with early postoperative thrombotic events, which can decrease perfusion to the graft. Addition of aminocaproic acid (Amicar) and protamine to whole blood samples studied by TEG[®] enables the anesthesiologist to accurately diagnosis and manage intraoperative coagulopathies. If signs of fibrinolysis are seen on TEG[®] with clinical signs of bleeding, antifibrinolytic medication such as ϵ aminocaproic acid must be titrated to correct the TEG[®] pattern and reduce blood loss. Likewise, if there are signs of a heparin effect (potentially from the grafted tissues) on TEG[®] associated with clinical findings, protamine can be titrated to a similar endpoint. Administration of platelets and FFP in a timely manner is critical for the surgical success and patient survival. The challenge in accurately estimating blood loss is well established. Without proper management, large amounts of blood loss can occur during these procedures either from oozing at the surgical site or frank bleeding during tourniquet deflation as discussed earlier. We recommend the use of a cell saver and reliance on the RIS to achieve hemodynamic stability and to normalize ABGs. The estimated blood loss is recorded as the amount of RIS infusate used during the procedure to maintain patient stability. As surgical technique and expertise evolve and improve for upper extremity transplantation, it is anticipated that the requirement for blood products will be reduced. It has been shown in forearm transplantation that low perfusion pressure after clamp release following microvascular anastomoses can exacerbate cold ischemia and negatively affect graft outcomes both in terms of functional return as well as increased risk of acute rejection.³⁶ Taken together, the PUETAP advocates for a balanced infusate of blood products (PRBC and FFP) to recipients during surgery, maintenance of stable hemodynamics through the use of the RIS, and proactive replacement of consumed clotting factors before development of coagulopathy. The PUETAP emphasizes the role of frequent monitoring of blood chemistries, ABGs, coagulation measurements by TEG[®], and the use of supraclavicular brachial plexus blocks under ultrasound guidance.

The immunologic, functional, and graft survival outcomes are not the focus of this article and are currently in

review as part of a separate article. In upper extremity transplants, each tissue has distinct immunogenicity. Keratinocytes and Langerhans cells in the skin are highly antigenic. Thus, high-dose multidrug immunosuppression is necessary for the life of the graft to prevent rejection.^{37,38,39} Initial treatment with an antibody targeting recipient immune cells followed by triple-drug maintenance therapy remains the current standard in VCA. Acute graft rejection is treated with increases in systemic drug dosing or topical (cream) medications. However, the primary obstacle to wider and routine feasibility of upper extremity transplantation is toxicity of prolonged, high-dose immunosuppression. Minimization of immunosuppression is an immediate need in these promising reconstructive procedures to improve the benefit-risk consideration in recipients.⁴⁰

The Pittsburgh Protocol of immunomodulation combines a stem cell-based therapy including DBMI with tacrolimus maintenance monotherapy and has enabled reduction of the overall need for the number and dosing of immunosuppression. The preliminary leukapheresis of recipients is to ensure that cryopreserved T cells are available to treat the remote risk of GVHD due to whole DBMI. The underlying basis of the protocol has been published earlier.^{15,16,40} Briefly, lymphocyte depletion (accomplished by a lytic monoclonal antibody such as alemtuzumab) before the transplant is followed by a secondary stimulus with donor antigens in the form of a DBMI. The lymphocyte depletion offers a temporary “window” for clonal exhaustion and deletion of recipient mature effector cells. Donor stem cells delivered with the DBMI could facilitate immunodulation in the recipient via thymic “education” of naïve recipient T cells. Such phenomena could theoretically enable reduction in dosing, frequency, or duration of immunosuppression in select patients based on immunologic and clinical outcomes. Notably, in our patients, no chimerism was detected on flow cytometry and PCR assays at all time points of testing after transplantation. However, early and intermediate term data indicate that the Pittsburgh immunomodulatory protocol is effective in prolonging graft survival on single drug (systemic/topical) immunosuppression. It has enabled reduction of drug dosing in all patients after 1 year. Rejection episodes have been infrequent, mostly low-grade (Banff 1 to 11), and controlled by either topical or short-course bolus steroid or antibody treatment. Donor-specific antibodies have been low or in stable low levels in all patients. Regular correlation of clinical and immunopathologic findings helped to fine tune dosing adjustments. Functional progress has been on track for all patients who have adhered to medication and therapy as mandated.

The goal of this article is to propose recommendations for upper extremity transplant anesthesia for programs performing these procedures.⁴¹ Further accrual of experience by anesthesiology teams working with surgical teams performing these procedures will enable standardization of protocols based on clinical efficacy. Sharing of data between programs will also help statistically validate outcome measures that may not be otherwise possible because of small patient numbers at any given institution. Our experience emphasizes the need for proactive prevention and aggressive intervention for some common complications and challenges during these complex procedures.

Each aspect of the PUETAP ensures patient safety while maximizing transplant outcomes both intraoperatively and postoperatively. Ultimately, functional and graft survival outcomes depend on impeccable surgical technique, a customized anesthetic protocol (as immunosuppressive induction regimen and immunosuppressive protocols vary by institution) and rigorous immunologic monitoring with postoperative biopsies to monitor for signs of rejection, immunosuppressive management, and intense rehabilitation after surgery.^{42–48} ■■

DISCLOSURES

Name: R. Scott Lang, MD.

Contribution: This author helped analyze the data and write the manuscript.

Attestation: R. Scott Lang approved the final manuscript.

Name: Vijay S. Gorantla, MD, PhD.

Contribution: This author provided critical input and helped write the manuscript.

Attestation: Vijay S. Gorantla approved the final manuscript.

Name: Stephen Esper, MD, MBA.

Contribution: This author helped write the manuscript.

Attestation: Stephen Esper approved the final manuscript.

Name: Mario Montoya, MD.

Contribution: This author helped conduct the study and write the manuscript.

Attestation: Mario Montoya approved the final manuscript.

Name: Joseph E. Losee, MD, FACS, FAAP.

Contribution: This author helped write the manuscript.

Attestation: Joseph Losee approved the final manuscript.

Name: Ibtesam A. Hilmi, MB, ChB, FRCA.

Contribution: This author helped write the manuscript.

Attestation: Ibtesam A. Hilmi approved the final manuscript.

Name: Tetsuro Sakai, MD, PhD.

Contribution: This author helped write the manuscript.

Attestation: Tetsuro Sakai approved the final manuscript.

Name: W. P. Andrew Lee, MD.

Contribution: This author helped write the manuscript.

Attestation: W. P. Andrew Lee approved the final manuscript.

Name: Jay S. Raval, MD.

Contribution: This author helped write the manuscript.

Attestation: Jay S. Raval approved the final manuscript.

Name: Joseph E. Kiss, MD.

Contribution: This author helped write the manuscript.

Attestation: Joseph E. Kiss approved the final manuscript.

Name: Jaimie T. Shores, MD.

Contribution: This author helped write the manuscript.

Attestation: Jaimie Shores approved the final manuscript.

Name: Gerald Brandacher, MD.

Contribution: This author helped write the manuscript.

Attestation: Gerald Brandacher approved the final manuscript.

Name: Raymond M. Planinsic, MD.

Contribution: This author helped design the study, conduct the study, analyze the data, and write the manuscript.

Attestation: Raymond M. Planinsic approved the final manuscript.

This manuscript was handled by: Edward C. Nemergut, MD.

REFERENCES

- Shores J, Shores JT, Brandacher G, Schneeberger S, Gorantla VS, Lee WPA. Composite tissue allotransplantation (VCA): hand transplantation and beyond. *J Am Acad Orthop Surg* 2010;18:127–31
- Brandacher G, Gorantla VS, Lee WP. Hand allotransplantation. *Semin Plast Surg* 2010;24(1):11–7

3. Ravindra KV, Wu S, Bozulich L, Xu H, Breidenbach WC, Ildstad ST. Composite tissue transplantation: a rapidly advancing field. *Transplant Proc* 2008;40:1237–48
4. Ravindra KV, Wu S, McKinney M, Xu H, Ildstad ST. Composite tissue allotransplantation: current challenges. *Transplant Proc* 2009;41:3519–28
5. Gorantla VS, Demetris AJ. Acute and chronic rejection in upper extremity transplantation: what have we learned? *Hand Clin* 2011;27:481–93
6. Hautz T, Brandacher G, Zelger B, Gorantla VS, Lee AW, Pratschke J, Schneeberger S. Immunologic aspects and rejection in solid organ versus reconstructive transplantation. *Transplant Proc* 2010;42:3347–53
7. Schneeberger S, Gorantla VS, van Riet RP, Lanzetta M, Vereecken P, van Holder C, Rorive S, Rummelink M, Le Moine A, Abramowicz D, Zelger B, Kaufman CL, Breidenbach WC, Margreiter R, Schuind F. Atypical acute rejection after hand transplantation. *Am J Transplant* 2008;8:688–96
8. Schneeberger S, Gorantla VS, Hautz T, Pulikkottil B, Margreiter R, Lee WP. Immunosuppression and rejection in human hand transplantation. *Transplant Proc* 2009;41:472–5
9. Hartzell TL, Benhaim P, Imbriglia JE, Shores JT, Goitz RJ, Balk M, Mitchell S, Rubinstein R, Gorantla VS, Schneeberger S, Brandacher G, Andrew Lee WP, Azari KK. Surgical and technical aspects of hand transplantation: is it just another replant? *Hand Clin* 2011;27:521–30
10. Azari KK, Imbriglia JE, Goitz RJ, Shores JT, Balk ML, Brandacher G, Schneeberger S, Gorantla V, Lee WP. Technical aspects of the recipient operation in hand transplantation. *J Reconstr Microsurg* August 2, 2011 (Epub ahead of print)
11. Borgman MA, Spinella PC, Holcomb JB, Blackbourne LH, Wade CE, Lefering R, Bouillon B, Maegele M. The effect of FFP:RBC ratio on morbidity and mortality in trauma patients based on transfusion prediction score. *Vox Sang* 2011; 101:44–54. doi: 10.1111/j.1423-0410.2011.01466.x
12. Breschan C, Kraschl R, Jost R, Marhofer P, Likar R. Axillary brachial plexus block for treatment of severe forearm ischemia after arterial cannulation in an extremely low birth-weight infant. *Paediatr Anaesth* 2004;14:681–4
13. Hingorani AP, Ascher E, Gupta P, Alam S, Marks N, Schutzer RW, Mutyala M, Shiferson A, Yorkovich W, Jacob T, Salles-Cunha S. Regional anesthesia: preferred technique for venodilation in the creation of upper extremity arteriovenous fistulae. *Vascular* 2006;14:23–6
14. Tuman KJ, McCarthy RJ, March RJ, DeLaria GA, Patel RV, Ivankovich AD. Effects of epidural anesthesia and analgesia on coagulation and outcome after major vascular surgery. *Anesth Analg* 1991;73:696–704
15. Donnenberg AD, Gorantla VS, Schneeberger S, Moore LR, Brandacher G, Stanczak HM, Koch EK, Lee WA. Clinical implementation of a procedure to prepare bone marrow cells from cadaveric vertebral bodies. *Regen Med* 2011;6:701–6
16. Gorantla VS, Schneeberger S, Moore LR, Donnenberg VS, Zimmerlin L, Lee WP, Donnenberg AD. Development and validation of a procedure to isolate viable bone marrow cells from the vertebrae of cadaveric organ donors for composite organ grafting. *Cytotherapy* September 12, 2011 (Epub ahead of print)
17. Cendales LC, Kanitakis J, Schneeberger S, Burns C, Ruiz P, Landin L, Rummelink M, Hewitt CW, Landgren T, Lyons B, Drachenberg CB, Solez K, Kirk AD, Kleiner DE, Racusen L. The Banff 2007 working classification of skin containing composite tissue allograft pathology. *Am J Transplant* 2008;8:1396–400
18. Kanitakis J. The challenge of dermatopathological diagnosis of composite tissue allograft rejection: a review. *J Cutan Pathol* 2008;35:738–44
19. Deeg HJ. GVHD-free with Campath? *Blood* 2011;118:2033–4
20. Lovasik D, Foust DE, Losee JE, Lee WP, Brandacher G, Gorantla VS. Helping hands: caring for the upper extremity transplant patient. *Crit Care Nurs Clin North Am* 2011; 23:505–17
21. Breidenbach WC, Gonzales NR, Kaufman CL, Klapheke M, Tobin GR, Gorantla VS. Outcomes of the first 2 Am hand transplants at 8 & 6 years posttransplant. *J Hand Surg [Am]* 2008;33:1039–47
22. Lanzetta M, Petruzzo P, Dubernard JM, Margreiter R, Schuind F, Breidenbach W, Noll R, Schneeberger S, van Holder C, Gorantla VS, Pei G, Zhao J, Zhang X. Second report (1998–2006) of the International Registry of Hand and Composite Tissue Transplantation. *Transpl Immunol* 2007; 18:1–6
23. Lee J, Garcia AM, Lee WP, Munin MC. Inpatient rehabilitation challenges in a quadrilateral amputee after bilateral hand transplantation. *Am J Phys Med Rehabil* 2011;90:688–93
24. Ku G, Ting WC, Lim ST, Lee BT, Calne RY. Life-threatening coagulopathy associated with use of Campath (alemtuzumab) in maintenance steroid-free renal transplant given before surgery. *Am J Transplant* 2008;8:884–6
25. Christopherson R, Beattie C, Frank SM, Norris EJ, Meinert CL, Gottlieb SO, Yates H, Rock P, Parker SD, Perler BA. Perioperative morbidity in patients randomized to epidural or general anesthesia for lower extremity vascular surgery. Perioperative Ischemia Randomized Anesthesia Trial Study group. *Anesthesiology* 1993;79:422–34
26. Moraca RJ, Sheldon DG, Thirlby RC. The role of epidural anesthesia and analgesia in surgical practice. *Ann Surg* 2003;238:663–73
27. Su HH, Lui PW, Yu CL, Liew CS, Lin CH, Lin YT, Chang CH, Yang MW. The effects of continuous axillary brachial plexus block with ropivacaine infusion on skin temperature and survival of crushed fingers after microsurgical replantation. *Chang Gung Med J* 2005;28:567–74
28. Shemesh D, Olsha O, Orkin D, Raveh D, Goldin I, Reichenstein Y, Zigelman R. Sympathectomy-like effects of brachial plexus block in arteriovenous access surgery. *Ultrasound Med Biol* 2006;32:817–22
29. Liu SS, Ngeow JE, Yadeau JT. Ultrasound-guided regional anesthesia and analgesia: a qualitative systematic review. *Reg Anesth Pain Med* 2009;34:47–59
30. Favaloro EJ. Laboratory testing in disseminated intravascular coagulation. *Semin Thromb Hemost* 2010;36:458–67. Epub July 7, 2010
31. Jablecki J, Kaczmarzyk L, Domanasiewicz A, Chelmoński A, Kaczmarzyk J. Unsuccessful attempt of forearm transplantation—case report. *Ann Transplant* 2010;15:53–6
32. Edrich T, Pomahac B, Lu JT, Couper GS, Gerner P. Perioperative management of partial face transplantation involving a heparin antibody-positive donor. *J Clin Anesth* 2011;23:318–21
33. Tan CW, Ward CM, Morel-Kopp MC. Evaluating heparin-induced thrombocytopenia: the old and the new. *Semin Thromb Hemost* 2012;38:135–43
34. Ardlie NG, Cameron HA, Garrett J. Platelet activation by circulating levels of hormones: a possible link in coronary heart disease. *Thromb Res* 1984;36:315–22
35. Cerutti E, Stratta C, Romagnoli R, Schellino MM, Skurzak S, Rizzetto M, Tamponi G, Salizzoni M. Thromboelastogram monitoring in the perioperative period of hepatectomy for adult living liver donation. *Liver Transpl* 2004;10:289–94
36. Landin L, Cavadas PC, Garcia-Cosmes P, Thione A, Vera-Sempere F. Perioperative ischemic injury and fibrotic degeneration of muscle in a forearm allograft: functional follow-up at 32 months post transplantation. *Ann Plast Surg* 2011;66:202–9
37. Baumeister S, Kleist C, Döhler B, Bickert B, Germann G, Opelz G. Risks of allogeneic hand transplantation. *Microsurgery* 2004;24:98–103
38. Jones NF. Concerns about human hand transplantation in the 21st century. *J Hand Surg Am* 2002;27:771–87
39. Siemionow MZ, Zor F, Gordon CR. Face, upper extremity, and concomitant transplantation: potential concerns and challenges ahead. *Plast Reconstr Surg* 2010;126:308–1
40. Gorantla VS, Brandacher G, Schneeberger S, Zheng XX, Donnenberg AD, Losee JE, Lee WP. Favoring the risk-benefit balance for upper extremity transplantation—the Pittsburgh Protocol. *Hand Clin* 2011;27:511–20

Confidential Galley Proof. Not For Distribution.

41. Ravindra KV, Gorantla VS. Development of an upper extremity transplant program. *Hand Clin* 2011;27:531–8
42. Kvernmo HD, Gorantla VS, Gonzalez RN, Breidenbach WC. Hand transplantation—a future clinical option? *Acta Orthopædica Scandinavica* 2005;76:14–27
43. Breidenbach WC, Tobin GR, Gorantla VS, Gonzalez RN, Granger DK. A position statement in support of hand transplantation. *J of Hand Surgery (Am)* 2002;27:760–70
44. Gorantla VS, Barker JH, Jones JW Jr., Prabhune KA, Maldonado C, Granger DK. Immunosuppressive agents in transplantation: mechanisms of action and current anti-rejection strategies. *Microsurgery* 2000;20:420–9
45. Schneeberger S, Landin L, Kaufmann C, Gorantla VS, Brandacher G, Cavadas P, Lee WP, Breidenbach WC, Margreiter R. Alemtuzumab: key for minimization of maintenance immunosuppression in reconstructive transplantation? *Transplant Proc* 2009;41:499–502
46. Petit F, Minns AB, Dubernard JM, Hettiaratchy S, Lee WP. Composite tissue allotransplantation and reconstructive surgery: first clinical applications. *Ann Surg* 2003;237:19–25
47. Tai C, Goldenberg M, Schuster KM, Kann BR, Hewitt CW. Composite tissue allotransplantation. *J Invest Surg* 2003;16:193–201
48. Thauinat O, Badet L, El-Jaafari A, Kanitakis J, Dubernard JM, Morelon E. Composite tissue allograft extends a helping hand to transplant immunologists. *Am J Transplant* 2006;6:2238–42